

ISSN: 2413-9122
e-ISSN: 2518-7295
Volume 2 No. 3, September 2017



The Official Journal of the
Azerbaijan Medical Association

AMAJ

AZERBAIJAN MEDICAL ASSOCIATION JOURNAL



Pathophysiology

Original Article

The effect of chrysin on liver damage induced by subchronic toxicity of formaldehyde in rats

Mahmut Cay · Evren Kose · Azibe Yildiz · Osman Ciftci · Nigar Vardi · Sinan Bakirci · Deniz Senol · Songul Cuglan · Zulal Oner · Nihat Ekinçi - 42

Psychiatry

Case Report

A case of Munchausen syndrome presenting as a Cushing syndrome in a patient with major depressive disorder: a case report

Habib Erensoy · Mine Ozkan · Mitra Niafar · Sepideh Tahsini Tekantapeh - 48

Orthopaedics & Traumatology

Case Report

Functional outcome after posterior lumbar interbody fusion with cage in patient with lumbar spinal stenosis

Michael Horeb · Karya Triko Biakto · Wilhelmus Supriyadi - 50

General Surgery

Original Article

Spontaneous intramural esophageal hematoma: complete healing without surgical intervention

Novruzov Namig · Aynur Safyeva · Emin Mammadov - 54

Cardiovascular Medicine

Case Report

Successful decision-making for therapy of the patient with a floating thrombus attached to ruptured atherosclerotic plaque in the ascending aorta

Tomasz Stankowski · Vusal Hajiyev · Alexander Bauer · Oliver Grimmig · Dirk Fritzsche - 57

Case Report

Early IVC thrombosis after central shunt surgery in young adult with uncorrected tetralogy of Fallot

Samira Valiyeva · Madina Yuzbashova · Ermanno Mazza · Rashad Mahmudov - 59

DOI

For information about DOIs and to resolve them, please visit www.doi.org


The Cover: The Heydar Aliyev Center.

The Heydar Aliyev Center is a building complex in Baku, Azerbaijan designed by Iraqi-British architect *Zaha Hadid* and noted for its distinctive architecture and flowing, curved style that eschews sharp angles. The center is named after Heydar Aliyev, the president of Azerbaijan Republic from October 1993 to October 2003.

In 2014, the Center won the Design Museum's *Design of the Year Award 2014* despite concerns about the site's human rights record. This makes Zaha Hadid the first woman to win the top prize in that competition.

Also, the Heydar Aliyev Center is one of the architectural pearl of Baku, that has been included in the list of the World's best architectural projects of 2014.

Photo courtesy:
www.heydaraliyevcenter.az



Editor in Chief

Nariman Safarli, MD, MPH

Associate Editors

Jamal Musayev, MD
Nadir Zeynalov MD, PhD
Nigar Sadiyeva, MD, PhD
Ilyas Akhund-zada, MD, PhD

Assistant Editors

Rauf Karimov, MD, PhD
Lana Yusufova, MD
Narmina Aliyeva, MD
Saida Talibova, MD
Rashida Abdullayeva, MD, PhD

Call for papers

Azerbaijan Medical Association invites authors to submit their papers to Azerbaijan Medical Association Journal - **AMAJ**.

Authors preparing manuscripts for submission to **AMAJ** should consult Information for Authors available from journal site: www.amaj.az

Adherence to the instructions will prevent delays both in acceptance and in publication. Please, submit your publications to: <http://my.ejmanager.com/amaj/>

•••

The **AMAJ** staff continually seeks to expand our list of highly qualified reviewers. Reviewers receive manuscripts electronically and are asked to review them and return comments within 3 weeks. All reviews must be completed online. Guidelines for reviewers are available at www.amaj.az

•••

All articles published, including editorials, letters, and book reviews, represent the opinions of authors and do not reflect the policy of Azerbaijan Medical Association, the Editorial Board, or the institution with which the author is affiliated, unless this is clearly specified.

•••

Copyright 2016 Azerbaijan Medical Association. All rights reserved. Reproduction without permission is prohibited.

For further information please contact:
MD Publishing House, Istiqlaliyyet 37/2,
AZ1000, Baku, Azerbaijan
Tel: (+99455) 328 1888, email: editorial@amaj.az

Editorial Board

Aghakishi Yahyayev, MD, PhD
Baku, Azerbaijan

Ali Quliyev, MD, PhD
Baku, Azerbaijan

Anar Aliyev, MD, PhD
Baku, Azerbaijan

Elnur Farajov, MD, PhD
Baku, Azerbaijan

Erkin Rahimov, MD, PhD
Baku, Azerbaijan

Ferid Aliyev, MD, PhD
Baku, Azerbaijan

Ikram Rustamov, MD, PhD
Baku, Azerbaijan

Islam Magalov MD, PhD, DSc
Baku, Azerbaijan

Kamran Salayev, MD, PhD
Baku, Azerbaijan

Lale Mehdi, MD, PhD
Baku, Azerbaijan

Mirjalal Kazimi, MD, PhD
Baku, Azerbaijan

Mushfig Orujov MD, PhD
Baku, Azerbaijan

Qulam Rustamzade, MD, PhD
Baku, Azerbaijan

Nuru Bayramov, MD, PhD, DSc
Baku, Azerbaijan

Parviz Abbasov, MD, PhD, DSc
Baku, Azerbaijan

Ramin Bayramli, MD, PhD
Baku, Azerbaijan

Rashad Mahmudov MD, PhD, DSc
Baku, Azerbaijan

Turab Janbakhishov, MD, PhD
Baku, Azerbaijan

Tural Galbinur MD, PhD, DSc
Baku, Azerbaijan

Vasif Ismayil, MD, PhD
Baku, Azerbaijan

International Advisory Committee

Abass Alavi, MD, PhD, DSc
Philadelphia, PA, USA

Alessandro Giamberti, MD, PhD
Milan, Italy

Andrey Kehayov, MD, PhD, DSc
Sofia, Bulgaria

Ayaz Aghayev, MD, PhD
Cambridge, MA, USA

Bülent Gürler, MD, PhD
Istanbul, Turkey

Ercan Kocakoç, MD, PhD
Istanbul, Turkey

Faik Orucoglu, MD, PhD
Istanbul, Turkey

Fidan Israfilbayli, MD, PhD
Birmingham, UK

Gia Loblanidze, MD, PhD, DSc
Tbilisi, Georgia

Cuneyt Kayaalp, MD, PhD
Malatya, Turkey

James Appleyard, MD, PhD
London, UK

Jeff Blackmer, MD
Ottawa, Canada

Jochen Weil, MD, PhD, DSc
Hamburg, Germany

Kerim Munir, MD, MPH, DSc
Boston, MA, USA

Kisaburo Sakamoto, MD
Shizuoka, Japan

Nigar Sofiyeva, MD,
New Haven, CT, USA

Osman Celbis, MD, PhD
Malatya, Turkey

Rauf Shahbazov, MD, PhD
Dallas, Texas, USA

Rovnat Babazade, MD, PhD
Galveston, Texas, USA

Sarah Jane Spence, MD, PhD
Cambridge, MA, USA

Shirin Kazimov, MD, MPH, sPhD
Wheaton, IL, USA

Steven Toovey, MD, PhD
Basel, Switzerland

Taylan Kav, MD, PhD
Ankara, Turkey

Yusif Hacıyev, MD, PhD
Columbus, OH, USA



The Effect of Chrysin on Liver Damage Induced By Subchronic Toxicity of Formaldehyde in Rats

Mahmut Cay, PhD¹
Evren Kose, MD, PhD²
Azibe Yildiz, PhD³
Osman Ciftci, PhD⁴
Nigar Vardi, PhD³
Sinan Bakirci, MD⁵
Deniz Senol, PhD²
Songul Cuglan, PhD²
Zulal Oner, PhD⁶
Nihat Ekinci, PhD⁷

¹ Department of Anatomy, Faculty of Medicine, Uşak University, Uşak, Turkey

² Department of Anatomy, Faculty of Medicine, Inonu University, Malatya, Turkey

³ Department of Histology and Embryology, Faculty of Medicine, Inonu University, Malatya, Turkey

⁴ Department of Medical Pharmacology, Faculty of Medicine, Inonu University, Malatya, Turkey

⁵ Department of Anatomy, Faculty of Medicine, Duzce University, Duzce 81620, Turkey

⁶ Department of Anatomy, Faculty of Medicine, Karabük University, Karabük, Turkey

⁷ Department of Anatomy, Faculty of Medicine, Erciyes University, Kayseri, Turkey

Correspondence:

Mahmut Cay, PhD

Department of Anatomy, Faculty of Medicine, Uşak University, Uşak, Turkey
Phone: +90 541 2048387

Email: mahmut.cay@usak.edu.tr

Objective: This study examines the adverse effects of intraperitoneally administered formaldehyde (FA) on liver and potential protective effects of chrysin (CH) against FA exposure.

Methods: 42 Wistar albino male rats were divided into 6 groups as follows: group I: control; group II: CH (50 mg/kg); group III: 0.1 mg/kg Formaldehyde (FA-0,1); group IV: 1 mg/kg Formaldehyde (FA-1); group V: CH (50 mg/kg) treatment and 0,1 mg/kg formaldehyde application (FA-0,1+CH); group VI: CH (50 mg/kg) treatment and 1 mg/kg formaldehyde application (FA-1+CH). At the end of the investigation, the livers were removed.

Results: The levels of thiobarbituric acid reactive substances (TBARS), decreased glutathione (GSH), catalase (CAT) and superoxide dismutase (SOD) in liver sections were analyzed. In the groups that received only FA, a significant increase in the levels of TBARS, GSH and CAT was observed as markers of oxidative stress, while the SOD levels significantly decreased. In the groups treated both with FA and CH, the biochemical values were partially corrected towards those of the control group. In addition, the liver tissues were examined histologically. Histopathological damage was observed in the livers of rats treated with FA alone, but the lesions were less severe or were absent in the rats treated with both FA and CH.

Conclusion: FA exposure causes severe damage to liver and CH can be said to have a protective effect against such damages.

Keywords: Formaldehyde, chrysin, liver, antioxidant, histopathological damage, biochemistry.

Introduction

Formaldehyde (FA) is a colorless chemical that is readily soluble in water and has a very strong and distinctive odor. It is the simplest member of the aldehyde family [1, 2]. Exposure to FA occurs through skin contact, inhalation or through oral exposure. After entering into the body, FA is oxidized to formic acid in liver and erythrocytes. It is the enzyme formaldehyde dehydrogenase (FDH) that oxidizes FA [3]. In the reaction in which FDH takes a catalytic role, glutathione acts as a cofactor. Formic acid excreted in the urine or feces, or broken down to carbon dioxide and eliminated via

lungs [1-5]. FA has toxic effects on some systems including the respiratory, central nervous and digestive systems [6, 7]. FA is widely used in many substances that we use in our daily lives such as industrial products, cleaning materials and cosmetic products, and in most of the work areas. The toxic effects of FA exposure on skin, eyes, testes, respiratory system, central nerve system and digestive system have been confirmed by various studies [5].

Experimental studies have reported that FA causes centrilobular vacuolization and focal cellular necrosis in the liver. Administration of FA to rats has been to cause

mononuclear cell infiltration in liver tissues in the portal area and around central veins [8].

Given their chemical structure and biological functions, flavonoids are among the most important compounds in the phenol groups [9, 10]. The potent antioxidant activity they have is considered as one of the most important properties of flavonoids. Studies have shown that they are usually distributed in plants and cannot be synthesized by humans [10-14]. Chrysin (CH) is one of the flavonoids on which a large number of studies have been conducted in recent years. There are various studies on the effects of CH, that sought to detect the mechanisms of how these effects occur in the target systems. CH is believed to contribute to the prevention of toxic effect and cancer development by means of decreasing the level of free radicals and inactivating carcinogens Based on the findings of these studies, mostly conducted on animals, CH is believed to have anticarcinogenic [15-18], antioxidant [19-21], anti-inflammatory [22] and antiviral [23] properties.

In the light of this information, we studied the liver damage that might be induced by exposure to low concentrations of FA. As a protective substance, we used CH which has potent antioxidant properties against liver damage.

Material and Methods

This study was performed with permission in Inonu University Experimental Animals Ethic Committees (Protocol no: 2011/A-58). In our study, three-month-old male Wistar albino rats, weighing between 250 and 300 g, were used and were divided into 6 groups with 7 rats in each group. The rats were housed in separate cages in standard conditions, with a 12/12 h light-dark cycle and were given standard rat chow and water ad libitum in Inonu University Experimental Animals Laboratory. Two different concentrations of FA were administered.

Group 1: Control group was treated orally with 50 mg/kg corn oil.

Group 2: Group CH was treated orally with 50 mg/kg CH (CH 97%, Sigma-Aldrich C80105, Germany) dissolved in corn oil [19, 20].

Group 3: Group FA-0.1 received intraperitoneal injection of 0.1 mg/kg FA (formalin, Sigma-Aldrich Formaldehyde 37% solution, Deisenhofen, Germany).

Group 4: Group FA-1 received intraperitoneal injection of 1 mg/kg FA.

Group 5: Group FA-0.1+CH was treated with both CH (50 mg/kg) and FA (0.1 mg/kg).

Group 6: Group FA-1+CH was treated with both CH (50 mg/kg) and FA (1 mg/kg).

Treatment with FA and CH was given three times a week for a period of 60 days. In the groups that received both FA and CH, CH was administered one day earlier. At the end of the experimental period, the rats were decapitated and liver tissues were dissected out for biochemical (TBARS, GSH, CAT and SOD) and histological analysis.

Biochemical Analysis

The liver tissue samples stored in a deep freezer at -80 °C were thawed and weighed on the day of analysis. The tissues were homogenized in ice-cold 10% phosphate buffer and the homogenate was centrifuged at 14968 xg (RCF) for 1 to 2 minutes (IKA, Germany). The tissue homogenates were then centrifuged at 3885 xg (RCF), at +4 °C for 30 minutes and the supernatant was collected.

Measurement of TBARS Levels: TBARS levels were determined using the method developed by Esterbauer and Cheeseman [24]. Malondialdehyde reacting with thiobarbituric acid in the acidic environment at 90-95°C was rapidly cooled following the formation of pink-colored chromogen. After 10 minutes, absorbance of the samples was read at a wavelength of 532 nm in a spectrophotometer. The results were expressed as nmol/g wet tissue weight.

Measurement of GSH Levels: GSH analysis was conducted using Ellman's reagent and the level of reduced glutathione was measured through reading the absorbance of yellow-green substance formed after reaction of glutathione with 5.5 dithio-bis-2-nitrobenzoic acid at a wavelength of 410 nm in a spectrophotometer [25].

Measurement of CAT Activity: Catalase activity was measured using the method developed by Aebi, through recording the decrease in absorbance that occurred after adding tissue samples to 50 mM phosphate buffer (pH 7.0) containing H₂O₂ (0.500) at 240 nm for 10 seconds [26].

Measurement of SOD Activity: SOD activity was measured based on the method developed by Sun et al., through determining the inhibition of nitroblue tetrazolium (NBT) reduction with an O₂⁻-generator [27].

The Method of Histological Analysis: Extracted liver tissues were fixed in 10% formaldehyde solution. After being washed in tap water, the samples were dehydrated and cleared, and then embedded in paraffin. 4-5 µm thick tissue sections were cut from the paraffin blocks. After the deparaffinization and rehydration processes, the tissue sections were stained with hematoxylin-eosin (H-E) and periodic acid-Schiff (PAS). Stained preparations were examined using a Leica DFC-280 light microscope. To detect liver damage, hepatocytes were examined based on the manifestations of swelling of cells, increased eosinophilia of the cytoplasm and loss of the glycogen content. The tissues were scored as follows: 0: no damage, 1: mild damage, 2: moderate damage and 3: severe damage. Kupffer cells were counted in 10 different areas of the tissues stained with periodic acid-Schiff (PAS) under x40 magnification.

Statistical Analysis

Normality of the data was analyzed with Shapiro-Wilk test. Mann Whitney U test was applied because the data did not show normality. IBM SPSS Statistics 22.0 software was used for the analysis. The data represented as arithmetic mean (X) +/- standard deviation (SD) and the significance level was set at 0.05.

Biochemical results

Biochemical results are given in Table 1. TBARS and GSH levels of FA-1 and FA 0,1 groups were significantly increased compared to control group. When the level of CAT of the FA-1 group was increased, SOD levels were significantly decreased compared to the control group.

The levels of the TBARS of the groups treated with FA and CH (Groups 5 and 6) were significantly decreased compared with the groups treated with FA only (Groups 3 and 4). The GSH levels of the FA-1+CH group were significantly decreased when compared to the FA-1 group.

Histological Results

Control and CH Groups

No abnormalities were discovered.

FA Groups

In sections stained with H-E, some hepatocytes had intensely eosinophilic cytoplasm and dark, pyknotic nuclei. Some hepatocytes were found to have pale and swollen cytoplasm due to hydropic changes (Fig. 1A, 1B).

Changes were more common and apparent in the hepatocytes from Group FA-1. The number of hepatocytes with increased eosinophilia was significantly increased in Group FA-1, as

compared to Group FA-0.1 (p=0.001). There was no statistically significant difference between the groups in terms of hydropic changes (p<0.05) (Table 2).

In addition, some of the sections from the FA groups exhibited apoptotic cells. Apoptotic cells were detected through their pyknotic nuclei and eosinophilic cytoplasm surrounded by a clear halo.

Another remarkable finding in the FA groups was the large number of binuclear hepatocytes observed in the sections (Fig. 1C, 1D).

In the sections stained with periodic acid-Schiff (PAS), it was observed that the number of PAS-positive hepatocytes decreased in the FA groups, as compared to the Control Group and CH groups (p=0.005). Although the decrease is greater in the Group FA-1 than in Group FA- 0.1, the difference between the groups was not statistically significant (p>0.05) (Table II).

In the FA groups, it was observed that the number of PAS-positive Kupffer cells increased significantly compared to the control group (Fig. 1E). The number of Kupffer cells in Group FA-1 increased significantly compared to Group FA-0.1

FA+CH Groups

Administration of CH did not have a statistically significant effect on the histological changes observed in Group FA-0.1 (p>0.05).

The number of hepatocytes with increased eosinophilic cytoplasm and decreased glycogen content observed in Group FA-1 decreased in Group FA-1+CH, but this decrease was not

Table 1. TBARS (thiobarbituric acid reactive substances), GSH (glutathione), SOD (superoxide dismutase) and CAT (catalase) analyses of liver tissues (The letters "a, b, c, d" in the same column show statistical differences).

Groups	TBARS (nmol/g tissue)	GSH (nmol/ml)	SOD (U/mg protein)	CAT (k/mg protein)
Control	3.62 ± 0.31 ^a	96.2 ± 2.77 ^a	4.04 ± 0.39 ^a	0.144 ± 0.024 ^{a,c}
CH	4.04 ± 0.32 ^a	95.8 ± 4.15 ^a	4.19 ± 0.40 ^a	0.103 ± 0.015 ^c
FA-0.1	5.43 ± 0.22 ^b	123.2 ± 2.89 ^{b,c}	3.15 ± 0.34 ^a	0.166 ± 0.015 ^a
FA-1	9.06 ± 0.45 ^c	170.2 ± 2.77 ^d	1.90 ± 0.26 ^b	0.275 ± 0.026 ^b
FA-0,1+CH	5.08 ± 0.27 ^b	103.3 ± 2.40 ^{a,b}	3.35 ± 0.33 ^a	0.179 ± 0.016 ^a
FA-1+CH	5.49 ± 0.19 ^b	117.3 ± 3.15 ^b	3.75 ± 0.26 ^a	0.200 ± 0.016 ^a
P value	0.001	0.002	0.001	0.003

- a – Significantly increased as compared to the Control Group, p= 0.0014
- b – Significantly decreased as compared to Group FA-1, p= 0.0014
- c – No significant difference as compared to Group FA-0.1+CH, p>0.05
- d – Significantly increased as compared to the Control Group, p= 0.0519
- e – Significantly increased as compared to the Control Group, p= 0,0005
- f – Significantly increased as compared to the Control Group, p< 0,0001
- g – No significant difference as compared to Group FA-1, p>0.05

Table 2. Results of the histological analysis of groups.

Groups	Hydropic Changes	Eosinophilic Hepatocytes	Loss of Glycogen Content	Number of Kupffer cells
Control	0.43 ± 0.30	0.14 ± 0.14	0.43 ± 0.20	5.37 ± 0.36
CH	0.57 ± 0.20	0.29 ± 0.18	0.57 ± 0.20	5.64 ± 0.35
FA-0.1	1.29 ± 0.18 ^{a,c}	0.86 ± 0.14 ^{c,d}	1.57 ± 0.20 ^{c,e}	7.44 ± 0.35 ^{c,f}
FA-1	2.29 ± 0.29 ^a	1.00 ± 0.3 ^d	1.86 ± 0.14 ^e	11.80 ± 0.38 ^f
FA-0,1+CH	1.14 ± 0.26 ^a	0.71 ± 0.18	1.43 ± 0.20	6.90 ± 0.33
FA-1+CH	1.29 ± 0.18 ^{a,b}	0.57 ± 0.20 ^g	1.71 ± 0.29 ^g	9.39 ± 0.35 ^b
P value	0.0014	0.0519	0.0005	< 0.0001

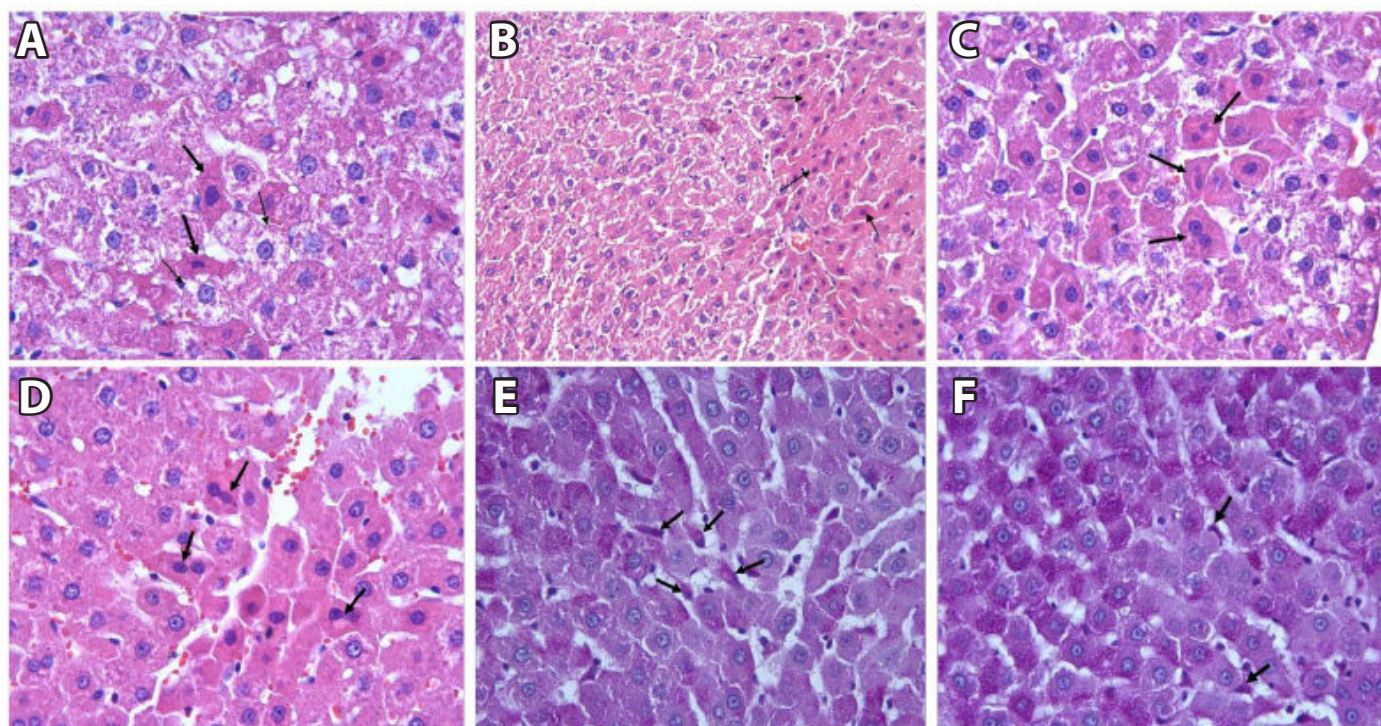


Figure 1.

A - Group FA-0.1- Hepatocytes with eosinophilic (thick arrows) and swollen (thin arrows) cytoplasm, H-E x40; **B** - Group FA-1- Hepatocytes with eosinophilic cytoplasm, H-E x20; **C** - Group FA-0.1- Binuclear hepatocytes (arrows); H-E X40; **D** - Group FA-1- Binuclear hepatocytes (arrows), H-E X40; **E** - Group FA-1- Kupffer cells (arrows), PAS X40; **F** - Group FA-1+CH- Decrease in the number of Kupffer cells compared to Group FA-1 can be seen (arrows), PASX40.

found to be statistically significant, though ($p > 0.05$). However, CH treatment decreased the number of Kupffer cells and significantly reduced the number of hydropic ($p = 0.001$ and $p < 0.0001$, respectively) (Fig. 1F) (Table II).

Discussion

This experimental study examined the liver damage induced by low concentrations of intraperitoneally injected FA in terms of biochemical and histological parameters. Moreover, the protective properties of CH, which is an important flavonoid, against these adverse effects were assessed. The histological and biochemical findings obtained at the end of the study were discussed and compared with the findings of other relevant studies.

FA is widely used in many substances that we use in our daily lives such as industrial products, cleaning materials and cosmetic products, and in most of the work areas [5, 28-30].

The toxic effects of FA exposure on skin, eyes, testes, respiratory system, central nerve system and digestive system have been confirmed by various studies [5, 31-36].

In an organism, there is a systematic balance between antioxidants, which have protective effects, and free radicals formed under a physiological or pathological activity. The shift of this balance in favor of the free radicals results in oxidative stress. Formed as a byproduct of lipid peroxidation, TBARS are considered as an important indicator in detecting oxidative stress [37, 38].

In this study, TBARS levels in the liver tissues from Group FA-1 and FA-0.1 were found to have increased significantly compared to the control group. Enzymatic and non-enzymatic antioxidant systems have a protective role against oxidative stress. Enzymatic antioxidant defense systems include CAT, SOD and GSH [34, 35]. In this study, it was observed that CAT and GSH enzyme activity levels in the liver tissue samples from Group FA-1 increased significantly, while there was a significant decrease in the SOD levels. On the other hand, a significant increase was observed in the GSH activity levels in Group FA-0.1, effects on the CAT and SOD activity levels were not found to be statistically significant.

In their study on rats, Zararsiz et al. reported that high concentrations of intraperitoneally injected FA (10 mg/kg) increased the CAT, SOD and GSH-Px activity levels in the liver tissues as well as increasing the levels of MDA which is a product of lipid peroxidation [39]. Farooqui et al. reported that high concentrations of intraperitoneally administered FA (72 mg/kg) increased glutathione concentration in secretion of bile, but decreased the levels of glutathione in the liver tissues [40]. Similarly, Skrzydlewska indicates that methanol is oxidized to formaldehyde and formate and increases the SOD and CAT activities in the rat liver tissues [41]. In their experimental study on isolated rat hepatocytes, Teng et al. found that even low concentrations of FA (500 μ l) caused oxidative stress [42]. Dobrzynska et al. reported an increase in the lipid peroxidation products in the livers of rats administered methanol (150 mg/kg) [43]. Such increase in the TBARS level is an indication of FA-induced lipid peroxidation

and oxidative stress in the liver tissues. In their experimental study, Gulec et al. found that there was a decrease in the SOD and CAT activity levels in the livers of rats administered FA (10 mg/kg) [44].

The biochemical data obtained in this study indicate that low concentrations of FA cause oxidative stress on liver, which is a finding compatible with the findings of the studies specified above [39-44]. Increased TBARS levels observed in this study indicate that low concentrations of FA can cause lipid peroxidation and oxidative stress in the liver tissues. A study reported that the levels of antioxidant enzyme SOD increased to balance the formation of excessive amounts of free radicals in acute pathologies. Since this study examines the subchronic toxicity, we believe that the decreased SOD levels observed are the result of the ongoing toxicity. Besides, increased transcription of GSH and CAT was observed due to the long-term exposure to FA. However, given the increased TBARS levels and other histological findings, we think that increased transcription was not sufficient to prevent toxicity.

Previous experimental studies found that FA also caused some changes in the microscopic structure of liver tissues. Beall and Ulsamer reported that exposure to formaldehyde can cause focal cellular necrosis and centrilobular vacuolization in the liver [8]. In the study by Zararsiz et al. light microscopic examination revealed vacuolization in the cytoplasm of some hepatocytes as well as some other hepatocytes with hyperchromatic nuclei [39]. Besides, they found that hepatocytes around the portal space were PAS-negative, which means there is no presence of glycogen. In this study, light microscopic examination of the H-E stained liver tissue sections from Group FA-1 and Group FA-0.1 revealed intense eosinophilia in the cytoplasm of some hepatocytes. It was found that changes were more common and apparent in the hepatocytes from Group FA-1. Besides, some of the sections from the FA groups exhibited apoptotic cells. In the FA groups, an increase was observed in the apparent number of Kupffer cells as compared to the control group. The apparent number of Kupffer cells in Group FA-1 increased significantly compared to Group FA-0.1. The findings of this study are compatible with those of previous studies in terms of the microscopic changes observed in the liver tissues after administering FA.

Flavonoids are compounds with beneficial biochemical and antioxidant effects found mainly and abundantly in plants, and CH is one of the best defined flavonoids [46-48]. Due to such potent antioxidant property of CH, we believed it could prevent liver damage induced by FA exposure. We examined the protective effects of CH against the liver damage that might be induced by FA exposure. Pushpavalli et al. reported changes in the CAT, SOD and GSH in favor of the control group following the use of CH on d-galactosamine administered rats as a protective agent [20]. In that study, the effects of chrysin and silymarin (silymarin is the most active ingredient of silibinin used in *Amanita phalloides* mushroom poisoning) were compared and the effect of chrysin was shown to be higher than that of silymarin. Similarly, in another study, chrysin has also been shown to improve glutamic oxaloacetic transaminase and glutamic pyruvate transaminase levels and decreased SOD,

CAT and GSH levels due to tissue damage in the liver in rats exposed to CCl₄ [49]. Forty to 50 grams of the *Amanita phalloides* fungus causes severe liver damage, sufficient to kill an adult man, due to the presence of a strong poison, α -amanitine. In the treatment of these fungal intoxications, silibinin, which is a partially beneficial substance, is used. In an in-vitro study conducted in recent years, the efficacy of chrysin versus silibinin on hepatotoxic effect was compared and a slight reduction in the hepatotoxic effect was seen in both drugs. This healing effect has been shown to be slightly greater with chrysin than with silibinin [50]. In a study conducted by Cuglan et al. in rats, it has been shown that damage to liver and kidneys occurs in fetuses due to formaldehyde exposure during pregnancy and decreases in given chrysin [51]. Sathivelu et al. also reported increased CAT, SOD, GSH levels and decreased TBARS levels in favor of the control group as a result of CH treatment as antioxidant against ethanol-induced oxidative stress in rat livers [21]. In addition, they indicated that the histological changes observed in their study were correlated with the biochemical findings. Ciftci and Ozdemir also used CH to prevent the 2,3,7,8-tetrachlorodibenzo-p-dioxin (TCDD) induced strong oxidative stress in rat livers and detected significant changes in the CAT, SOD, GSH and lipid peroxidation levels towards those of the control group [52]. They indicated that the histological changes observed in their study were correlated with the biochemical findings. In this study, biochemical analyses of the liver tissues revealed beneficial effects of chrysin in the FA-1+CH group. The TBARS, CAT and GSH levels significantly decreased, while the SOD activity levels significantly increased up to values close to the level of the control group. The CAT, SOD, GSH and TBARS levels in Group FA-0.1+CH also changed although the changes were not found to be statistically significant. It was observed that CH treatment prevented oxidative tissue damage in Group FA 1+CH at the biochemical level. Moreover, in groups treated with both FA and CH, the number of Kupffer cells decreased and cell swelling significantly reduced. However, there was no significant difference in terms of the number of eosinophilic hepatocytes and loss of glycogen content. The biochemical and histological findings obtained in this study regarding the antioxidant effect of CH are compatible with those of the previous studies.

Conclusion

The biochemical and histological findings obtained in this study reveal that FA exposure weakens the antioxidant defense system of liver, causing oxidative stress in the tissues. Furthermore, degeneration and apoptosis were observed in the histological structure of liver tissues following the FA administration. However, we found that chrysin treatment resulted in repression and regression of FA-induced oxidative tissue damage, microscopic changes and apoptosis in the liver tissues. In the light of these findings: It is important to investigate the therapeutic effect of chrysin depending on the dose. In addition, the use of formaldehyde should be reduced and occupational groups with higher exposure to formaldehyde should be encouraged to increase the number of investigations into chrysin's use as a preservative.

References

- Eells JT, Mc Martin KE, Black K, et al. Formaldehyde poisoning. Rapid metabolism to formic acid. *JAMA* 1981; 246: 1237-1238.
- Koivusalo M, Koivula T and Uotila L. Oxidation of formaldehyde by nicotinamid dependent dehydrogenases. *Prog Clin Biol Res* 1982; 114: 155-168.
- Bolt HM. Experimental toxicology of formaldehyde. *J Cancer Res Clin Oncol* 1987; 113: 305-309.
- Heck H and Casanova M. Pharmacodynamics of formaldehyde: Applications of a model for the arrest of DNA replication by DNA-protein cross-links. *Toxicol Appl Pharmacol* 1999; 160: 86-100.
- Collins JJ, Ness R, Tyl RW, et al. A review of adverse pregnancy outcomes and formaldehyde exposure in human and animal studies. *Regul Toxicol Pharmacol* 2001; 34: 17-34.
- Kriebel D, Myers D, Cheng M, et al. Short term effect of formaldehyde on peak expiratory flow and irritant symptoms. *Arch Environ Health* 2001; 56: 11-18.
- Sarsilmaz M, Kaplan S, Songur A, et al. Effects of postnatal formaldehyde exposure on pyramidal cell number, volume of cell layer in hippocampus and hemisphere in the rat: a stereological study. *Brain Res* 2007; 1145: 157-167.
- Beall JR and Ulsamer AG. Formaldehyde and hepatotoxicity. *J Toxicol Environ Health* 1984; 14: 1-21.
- Capanoglu E and Boyacioglu D. Meyve ve sebzelelerin flavonoid içeriği üzerine işlemenin etkisi. *Akademik Gıda* 2009; 7(6): 41-46.
- Robards K and Antolovich M. Analytical chemistry of fruit bioflavonoids: review. *The Analyst* 1997; 3: 122-130.
- Peterson J and Dwyer J. Flavonoids, dietary occurrence and biochemical activity. *Nutrition Research* 1998; 18 (12): 1995-2018.
- Shi H, Noguchi N and Niki E. Introducing Natural Antioxidants. In: Pokorny J, Yanishlieva N and Gordon M, (eds) *Antioxidants in Food, Practical Applications*. Boca Raton, 2001, pp.147-158.
- Sivam G. Analysis of Flavonoids. In: Hurst WJ (ed) *Methods of Analysis for Functional Foods and Nutraceuticals*. Boca Raton, 2002, 34p.
- Heim KE, Tagliaferro AR and Bobilya DJ. Flavonoid antioxidants: chemistry, metabolism and structure-activity relationships. *J Nutr Biochem* 2002; 13: 572-584.
- Yin F, Giuliano AE and Van Hearle AJ. Growth inhibitory effects of flavonoids in human thyroid cancer cell lines. *Thyroid* 1999; 9(4): 369-376.
- Yin F, Giuliano AE, Law RE et al. Apigenin inhibits growth and induces G2/M arrest by modulating cyclin CDK regulators and ERK MAP kinase activation in breast carcinoma cells. *Anticancer Res* 2001; 21(1A): 413-420.
- Zheng X, Meng WD, Xu YY et al. Synthesis and Anticancer Effect of Chrysin Derivatives. *Bioorg Med Chem Lett* 2003; 13: 881-884.
- Knowles LM, Zigrossi DA, Tauber RA et al. Flavonoids suppress androgen-independent human prostate tumor proliferation. *Nutr Cancer* 2000; 38(1): 116-122.
- Ciftci O, Ozdemir İ, Aydın M et al. Beneficial effects of chrysin on the reproductive system of adult male rats. *Andrologia* 2012; 44(3): 181-186.
- Pushpavalli G, Kalaiarasi P, Veeramani C et al. Effect of chrysin on hepatoprotective and antioxidant status in D-galactosamine-induced hepatitis in rats. *Eur J Pharmacol* 2010; 631(1-3): 36-41.
- Sathivelu J, Senapathy GJ, Devaraj R et al. Hepatoprotective effect of chrysin on prooxidant-antioxidant status during ethanol-induced toxicity in female albino rats. *J Pharm Pharmacol* 2009; 61(6): 809-817.
- Cho H, Yun CW, Park WK et al. Modulation of the activity of pro-inflammatory enzymes, COX-2 and iNOS, by chrysin derivatives. *Pharmacol Res* 2004; 49(1): 37-43.
- Critchfield JW, Butera ST and Folks TM. Inhibition of HIV activation in latently infected cells by flavonoid compounds. *AIDS Res Hum Retroviruses* 1996; 12: 39-46.
- Esterbauer H and Cheeseman KH. Determination of aldehydic lipid peroxidation products: Malonaldehyde and 4-hydroxynonenal. *Methods Enzymol* 1990; 186: 407-421.
- Moron MS, Depierre JW and Mannervik B. Levels of glutathione, glutathione reductase and glutathione S-transferase activities in rat lung and liver. *Biochim Biophys Acta* 1979; 582(1): 67-78.
- Aebi H. Catalase. In: Bergmeyer HU (ed) *Methods of Enzymatic Analysis*. New York and London 1974, pp, 673-677.
- Sun Y, Oberley LW and Li Y. A simple method for clinical assay of superoxide dismutase. *Clin Chem* 1988; 34: 497-500.
- Broder I, Corey P, Brasher P et al. Formaldehyde exposure and health status in households. *Environ Health Perspect* 1991; 95: 101-104.
- Feron VJ, Til HP, Vrijer F et al. Aldehydes: occurrence, carcinogenic potential, mechanism of action and risk assessment. *Mutat Res* 1991; 259: 363-85.
- Naya M and Nakanishi J. Risk assessment of formaldehyde for the general population in Japan. *Regul Toxicol Pharmacol* 2005; 43: 232-248.
- Krzyzanowski M, Quackenboss JJ and Lebowitz MD. Chronic respiratory effects of indoor formaldehyde exposure. *Environ Res* 1990; 52: 117-125.
- Canbilen A, Sezen Ş, Avunduk MC et al. Formaldehit ve toksik etkileri. *Genel Tıp Dergisi* 1999; 9: 33-39.
- Malek FA, Möritz KU and Fanghanel J. A study on the effect of inhalative formaldehyde exposure on water labyrinth test performance in rats. *Ann Anat* 2003; 185: 277-285.
- Yarıktas M, Doner F, Dogru H et al. Baş boyun malign tümörlerinde malondialdehit düzeyleri ve antioksidan enzim aktiviteleri. *SDÜ Tıp Fakültesi Dergisi* 2003; 1: 65-67.
- Zararsız İ, Kuş İ, Yılmaz HR et al. Siçan prefrontal korteksinde formaldehit maruziyetiyle oluşan oksidatif hasara karşı omega-3 yağ asitlerinin koruyucu etkisi. *Fırat Tıp Dergisi* 2004; 9: 35-39.
- Uchiyama S, Matsushima E, Kitao N et al. Effect of natural compounds on reducing formaldehyde emission from plywood. *Atmos Environ* 2007; 41(38): 8825.
- Khan MM, Evans DR, Vijayasudha G et al. Reduced erythrocyte membrane essential fatty acids and increased lipid peroxides in schizophrenia at the never-medicated first-episode of psychosis and after years of treatment with antipsychotics. *Schizophr Res* 2002; 58(1): 1-10.
- Oakes KD and Van Der Kraak GJ. Utility of the TBARS assay in detecting oxidative stress in white sucker (*Catostomus commersoni*) populations exposed to pulp mill effluent. *Aquat Toxicol* 2003; 63(4): 447-463.
- Zararsız İ, Sarsılmaz M, Sönmez MF et al. Kadavra Tespitinde Kullanılan Formaldehitin Siçan Karaciğerinde Oluşturduğu Hasar ve Buna Omega-3 Yağ Asitlerinin Etkisi. *Fırat Tıp Dergisi* 2005; 3: 103-107.
- Farooqui MY, Upreti RK, Ahmed AE et al. Influence of intraperitoneally administered formaldehyde on bile production and tissue glutathione levels in rats. *Res Commun Chem Pathol Pharmacol* 1986; 53: 233-236.
- Skrzydłowska E. Decreased antioxidant status and increased lipid peroxidation in rats after methanol intoxication. *Rocz Akad Med Białymst* 1996; 41: 397-404.
- Teng S, Beard K, Pourahmad J et al. The formaldehyde metabolic detoxification enzyme systems and molecular cytotoxic mechanism in isolated rat hepatocytes. *Chem Biol Interact* 2001; 130-132(1-3): 285-296.
- Dobrzynska I, Skrzydłowska E, Kasacka I et al. Protective effect of N-acetylcysteine on rat liver cell membrane during methanol intoxication. *Pharm Pharmacol* 2000; 52: 547-552.
- Gulec M, Gurel A and Armutcu F. Vitamin E protects against oxidative damage caused by formaldehyde in the liver and plasma of rats. *Mol Cell Biochem* 2006; 290(1-2): 61-67.
- Taysi S, Gul M, Sari RA et al. Oxidant/antioxidant status in serum of patients with systemic lupus erythematosus. *Clin Chem Lab Med* 2002; 40: 684-688.
- Medina JH, Paladini AC, Wolfman C et al. Chrysin (5,7-di-OH-flavone), a naturally-occurring ligand for benzodiazepine receptors, with anticonvulsant properties. *Biochem Pharmacol* 1990; 40(10): 2227-2231.
- Wolfman C, Viola H, Paladini A et al. Possible anxiolytic effects of chrysin, a central benzodiazepine receptor ligand isolated from *Passiflora coerulea*. *Pharmacol Biochem Behav* 1994; 47(1): 1-4.
- Lakhanpal P and Rai DK. Quercetin: a versatile flavonoid. *Internet Journal of Medical Update* 2007; 2(2): 22-37.
- Anand KV, Anandhi R, Pakkiyaraj M et al. Protective effect of chrysin on carbon tetrachloride (CCl4)-induced tissue injury in male Wistar rats. *Toxicol Ind Health* 2011; 27: 923-933.
- Bakırcı S, Bayram R, Kaya E et al. What is the restoring role of chrysin in alpha amanitin toxicity? *Acta Medica Mediterranea* 2015; 31: 1181.
- Cuglan S, Ekinçi N, Yıldız A et al. The role of chrysin against harmful effects of formaldehyde exposure on the morphology of rat fetus liver and kidney development. *Medicine Science* 2017; 6(1): 73-80.
- Ciftci O and Ozdemir İ. Protective effects of quercetin and chrysin against 2,3,7,8-tetrachlorodibenzo-p-dioxin (TCDD) induced oxidative stress, body wasting and altered cytokine productions in rats. *Immunopharmacol Immunotoxicol* 2011; 33(3): 504-508.



A Case of Munchausen Syndrome Presenting as a Cushing Syndrome in a Patient with Major Depressive Disorder: A Case Report

Habib Erensoy, MD¹
Mine Ozkan, MD²
Mitra Niafar, MD³
Sepideh Tahsini Tekantapeh, MD⁴

¹ Uskudar University, Psychiatry Department, Assistant Professor of Psychiatry, Istanbul, Turkey, habiberensoy@yahoo.com

² Medical Faculty of Istanbul University, Prof. of Psychiatry, Head of Consultation Liaison, Istanbul, Turkey, mineozkan_klp@yahoo.com

³ Endocrine Research Center, Professor in Endocrinology, Tabriz University of Medical Science, Tabriz, Iran, dr_niafar@yahoo.com

⁴ Endocrine Research Center, Internal Medicine Resident, Tabriz University of Medical Science, Tabriz, Iran, tahsinis@tbzmed.ac.ir

Correspondence:

Sepideh Tahsini Tekantapeh, MD

Endocrine Research Center, Tabriz University of Medical Science, Imamreza Hospital, Tabriz, Iran

Postal code: 51739-65673

Email: tahsinis@tbzmed.ac.ir

Munchausen's syndrome is a psychiatric problem in which patients inflict an illness on themselves with the aim of playing in the role of being sick. In this paper a 38-year-old woman with a history of MDD (Major Depressive Disorder) is introduced with uncontrolled hypertension, high blood sugar and cushingoid appearance in the result of high dose exogenous steroids injections secretly and without a prescription. She was interested in hospitalization by inducing hypertension crisis and hyperglycemia. Exogenous Cushing Syndrome was diagnosed according to laboratory findings and patient history during admission. Finally, Cushing Syndrome gradually improved over the months by psychotherapy and treatment with antidepressant drugs.

Keywords: Cushing Syndrome, factitious disorder, Major depressive disorder, Munchausen's syndrome.

Introduction

Munchausen's syndrome is a psychiatric problem in which patients inflict an illness on themselves with the aim of playing a role of being sick [1, 2]. Munchausen's syndrome classified as a factitious disorder in the latest version of Diagnostic and Statistical Manual of Mental Disorders (DSM-5) [3]. This disease is characterized by the intentional creation of physical or psychological signs and symptoms with a psychological need to receive treatment such as a patient [3]. This syndrome was first described by Richard Asher in 1951. This syndrome was named for Baron Karl Friedrich von Munchausen who was known to tell unrealistic, extraordinary and supramental stories about the wars he participated against the Ottoman Turks [4].

These patients are even willing to undergo invasive diagnostic procedures and surgeries in order to be in the spotlight or sympathize with patients who are truly sick. Thus, this syndrome is also sometimes named as 'hospital addiction syndrome',

'thick chart syndrome' or 'hospital hopper syndrome' [5].

There are no reliable statistics about the prevalence of this syndrome, but it is considered rare. Although any age group may be affected, most patients are women between 20 and 40 years [6]. Some theories indicate that a history of abuse or neglect in childhood and frequent illnesses that required admission may be effective factors in the development of this syndrome. Hypotheses about the relationship between this syndrome and personality disorders are studied [7].

Treatment for Munchausen's syndrome usually includes psychiatric counseling in order to change the thoughts and behaviors that cause this syndrome. Cognitive-behavioral therapy, family therapy, and group therapy are the possible effective treatment modalities of this disorder. Although there is no medication for the treatment of factitious disorder, psychotherapy for any possible underlying cause, such as depression, anxiety or personality disorder may be helpful [3].

Case Report

The patient is a 38-year-old woman, with a degree in primary school, married and has a child. Prednisolone 5mg/daily was started by a pulmonologist in the treatment of severing asthma 13 years ago for 2years and according to the patient, based on the physician's advice regarding potential drug side effects, she does not use steroid for a long time. During the last 5 years, she has been treated with citalopram 40 mg/day for MDD. She was admitted in endocrinology ward because of frequent episodes of uncontrolled hypertension, high BS (blood sugar) and myopathy during the last 6month that had not improved by outpatient treatment. Her face was cushingoid. Despite treatment with anti-hypertensive drugs and insulin, she was hospitalized for a month due to difficult blood pressure and BS control. Leucocytosis, hyperglycemia, and dyslipidemia were observed in the laboratory findings. In an approach to clinical evidence of hypercortisolism such as moon face, hypertension, myopathy and hyperglycemia beside low cortisol level and low ACTH, self-prescription corticosteroid injection was suspected. Psychiatric consultation was requested due to a suspicion of cortisone abuse in the result of Munchausen Syndrome. In an interview with a psychiatrist, the patient confessed using prednisolone 50 mg daily and weekly injections of dexamethasone from a long time despite the pulmonologist advise. She enjoyed the euphoria and well-being mood despite knowing chronic steroid use harmful effects. She had a good sense of getting sick and attract the attention of those around her was pleasant. Psychotherapy in parallel with medical treatment with Fluoxetine 40mg/daily and Sulpiride 50 mg was started. Gradually corticosteroid tapering under endocrinologist supervision successfully completed. BS with oral anti-glycemic agents is in goal range and blood pressure is control. Also, steroid induced myopathy improved. The patient was followed up in an outpatient setting and did not repeated steroid injections with no require to hospitalization.

Discussion

The importance of early diagnosis of the Munchausen Syndrome in addition to the patient's benefit from psychotherapy and drug treatment include reduced hospital bed occupancy and prevention of wasting the cost of health care system (8). In this case, a patient with the history of depression is presented with features of Cushing syndrome and medical problems such as uncontrolled hypertension, hyperglycemia, and myopathy in the result of Munchausen Syndrome. At first, she denied taking any other medication.

Clinical findings of Cushing's syndrome besides laboratory finding such as low serum cortisol and suppressed ACTH led us to psychologic problems involvement as the underlying cause to find a justification for secretly exogenous steroid injections. In the psychiatric interview, she confessed to secretly injections. The interesting point was that in the event of purposeful treatment of Munchausen Syndrome such as psychotherapy, antidepressant drugs and steroid tapering, optimal control of blood pressure and BS were observed without a need to admission.

Conclusion

This case show in dealing with a medical disease when all of the diagnostic and therapeutic procedure remains inconclusive, it is recommended "factitious disorders" or Munchausen Syndrome should be considered. Early diagnosis of the disease, will help in health cost savings and the correct use of hospital beds for real patients who require hospital admission.

References

1. Niafar M, Erensoy H, TEKANTAPEH ST. Recurrent diabetic ketoacidosis-like symptoms and factitious hyperglycemia as a Munchausen syndrome in diabetes mellitus type 1: a case report. ANADOLU PSIKIYATRI DERGISI-ANATOLIAN JOURNAL OF PSYCHIATRY. 2017 Feb 1;18:29-31.
2. Oner E, Unlu M, Solgun B, Kocyigit H, Cimen P. A CASE OF FACTITIOUS BLEEDING: MUNCHAUSEN'S SYNDROME. JOURNAL OF EVOLUTION OF MEDICAL AND DENTAL SCIENCES-JEMDS. 2015 Jun 15;4(48):8416-9.
3. American Psychiatric Association. Diagnostic and statistical manual of mental disorders (DSM-5®). American Psychiatric Pub; 2013 May 22.
4. Asher R. Munchausen's syndrome. The Lancet. 1951 Feb 10;257(6650):339-41.
5. Prakash J, Das RC, Srivastava K, Patra P, Khan SA, Shashikumar R. Munchausen syndrome: Playing sick or sick player. Industrial psychiatry journal. 2014 Jan;23(1):68.
6. Jaghab K, Skodnek KB, Padder TA. Munchausen's syndrome and other factitious disorders in children: case series and literature review. Psychiatry (Edgmont). 2006 Mar;3(3):46.
7. Alinejad NA, Oettel DJ. Factitious disorder as repeated diabetic ketoacidosis: a case report. Innovations in clinical neuroscience. 2011 Feb 1;8(2):41.
8. Karadsheh MF. Bloody tears: a rare presentation of munchausen syndrome case report and review. Journal of family medicine and primary care. 2015 Jan;4(1):132.



Functional Outcome After Posterior Lumbar Interbody Fusion With Cage in Patient With Lumbar Spinal Stenosis

Michael Horeb, MD¹
Karya Triko Biakto, PhD²
Wilhelmus Supriyadi, MD²

¹ Resident of Orthopaedic and Traumatology Departement, Hasanuddin University, Makassar, Indonesia

² Teaching Staff of Orthopaedic and Traumatology Departement, Hasanuddin University, Makassar, Indonesia

Correspondence:

Michael Horeb, MD

Orthopaedic and Traumatology Department, Hasanuddin University, Makassar, Indonesia.

Phone: +62 411 590190

Email: michael.horeb@gmail.com

Lumbar spinal stenosis is common degenerative disease of the spine in the elderly population. Posterior Lumbar Interbody Fusion (PLIF) is increasingly used to achieve 360° fusion and allows for adequate intervertebral foraminal height restoration for neural decompression while maintaining posterior support structures. The study purpose is to know the functional outcome after posterior lumbar interbody fusion with cage in patient with lumbar spinal stenosis.

The study was performed by using retrospective longitudinal study design with 16 patients who had undergone posterior lumbar interbody fusion procedure with cage at Wahidin Sudirohusodo Hospital, Makassar, within period December 2015 to September 2017, with follow up time of 6 months and 12 months postoperatively.

All patients were evaluated for pain scale assessment and Oswestry Disability Index and were analyzed using the Wilcoxon Signed Rank Test test, and the Somer's Dtest Test, with p value <0.05.

From the analysis there are improvement of pain scale and functional outcome in patients before and after operation.

Keywords: Lumbar spinal stenosis, Posterior Lumbar Interbody Fusion (PLIF), cage, functional outcome

Background

Lumbar spinal stenosis is a condition of narrowing of the spinal canal or intervertebral foramen in the lumbar region accompanied by suppression of nerve roots coming out of the foramen. Lumbar spinal stenosis is one of the most common problems, which is a degenerative disease of the spine in the elderly population. The prevalence of this disorder is 5 out of 1000 people over the age of 50 in America. It is the most common disease that causes surgery on the spine at the age of more than 60 years. [1-3, 6, 7]

This disorder is generally slow. Generally exposed to L3-L4, and L4-L5 areas. Symptoms may include lower back pain, neurogenic claudication, pain radiating to the extremities, reduced travel distance on the road, and limited mobility. Conservative

therapy may reduce symptoms, but underlying basic abnormalities remain and it is not possible to achieve excellent results with conservative therapy in a very long time.[4]

The goal of surgery is to get a complete decompression on the cauda equina and nerve root by minimizing damage to the spinal architecture. However, limited decompression is sometimes not enough, and re-stenosis may occur. On the other hand, extensive decompression may lead to instability after surgery, with architectural weakness in the vertebral structure. [2]

Operative procedures that can be performed include: decompressive laminotomy and partial fasetectomy, decompressive laminectomy and partial fasetectomy, micro decompression, decompression and fusion without instruments, decompression and fusion with instruments, decompression

and flexible stabilization, interspinous spacer device. [3]

The posterior Lumbar interbody fusion (PLIF) was first described by Cloward in 1940 and modified by Lin, after which it became one of the most common operations. PLIF can provide stable three-column fixation with anterior and 360° fusion support, and is performed only from the posterior. It also protects the instruments in the posterior part of the strain and failure in addition to restoring the height of the intervertebral discs, which can lead to nerve decompression. [5]

The aim of this study is to know the functional outcome of posterior lumbar interbody fusion with cage in patients with lumbar spinal stenosis.

Material and Methods

The study performed by using retrospective study design with 16 patients who had undergone posterior lumbar interbody fusion procedure with cage through a dorsal approach at Wahidin Sudirohusodo Hospital, Makassar, within period December 2015 to September 2017. Medical records of patients fulfilling inclusion and exclusion criteria were collected for height, body weight, Numeric Pain Rating Scale (NRS) and Oswestry Disability index (ODI) (In order to determine the effect of leg pain and low back pain on daily life activities) before surgery, and 6 months and 12 months postoperative.

The patient inclusion criteria were: (i) adult patients undergoing surgery for degenerative conditions of the lumbar spine, excluding tumour, trauma and infection, with a minimum follow-up of 1 year, (ii) age over 40 years, (iii) all operations are performed by the same surgeon.

All patients underwent a comprehensive neurologic exam-

ination. Pre-operative imaging included lumbosacral x-ray graphics (AP, Lateral), flexion-extension x-rays to demonstrate dynamic instability and MRI. Stenosis was not classified as foraminal and extraforaminal. All patients had posterior lumbar interbody fusion procedure with cage through a dorsal approach. All operations were performed by the same surgeon.

Wilcoxon Signed Rank test used to assess NRS and ODI comparison before operation, 6 months and 12 months postoperatively. The results of the comparison differed significantly if the p value <0.05. Somer's d test used to assess the ratio of preoperative disability to 6 months and 12 months postoperatively. The results of the comparison differed significantly if the p value <0.05.

Surgical Technique

Preoperative antibiotic prophylaxis was done by intravenous cefazolin 1 g one hour before surgery. The patient underwent a generalized endotracheal anesthetic procedure and positioned prone on the operating table or a framework to lower the pressure in the abdomen. Approach posterior routine through the midline incision 10 cm, so it looks lumbar vertebra. Then performed the decompression procedure by means of total facetectomy, laminectomy, resection of the flavum ligament in the affected segment. After the disectomy, the end plate of the vertebral body is cleansed. Proper cage installation is performed. In all cases, an autogenous local bone graft from bone originated from the previous decompression procedure to achieve fusion. The bone used is cleaned from the connective tissue, then the cancellous bone is placed in the cage. Then performed spondylolisthesis correction using two rods according to standard operating protocol. The remaining bone is then used as an autogen corticocancellous graft placed posterolaterally (Fig. 1).

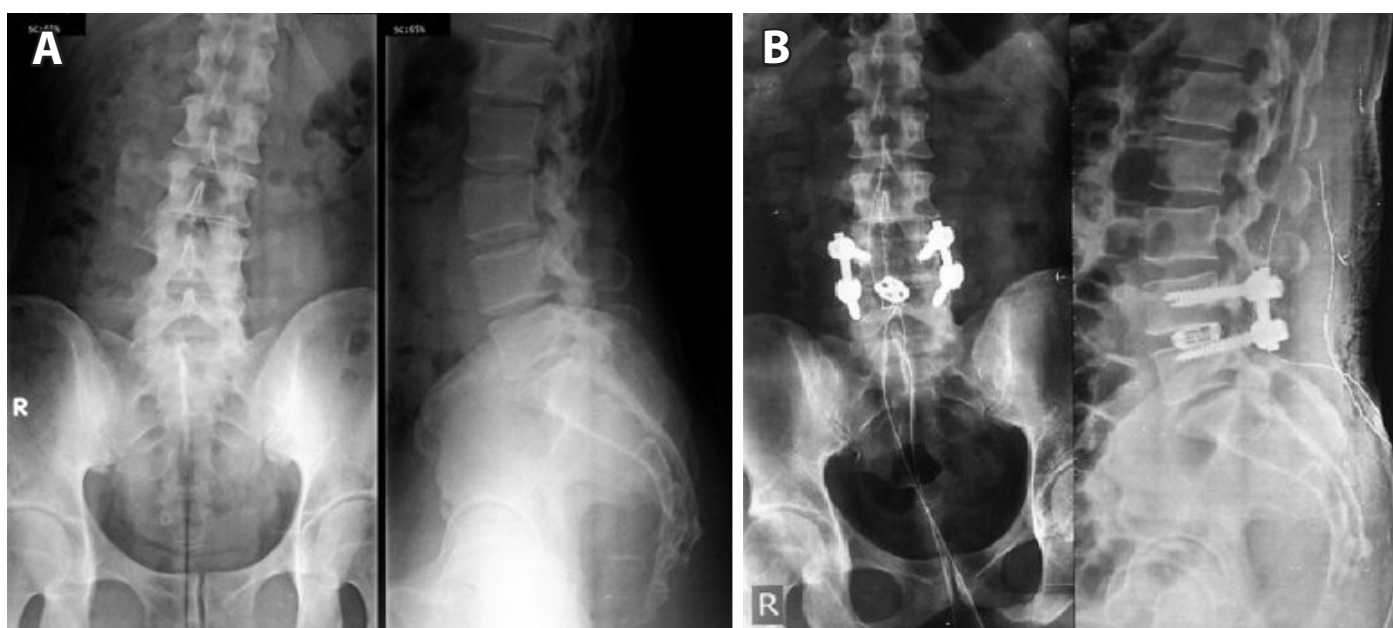


Figure 1. Radiological features before (A) and after (B) PLIF with cage procedure.

Results

The study included 16 patients, mostly male (62.5%). The age of the study subjects was between 44-78 years with mean (mean) of 57 years. Majority of patients including overweight, with BMI between 20.3-28.3 and 24.5. The location of the operation was mostly carried out on L4-L5 (68.8%) (Tab 1).

The 6-month postoperative NRS was significantly lower than the preoperative NRS score of 6.00 down to 3.56, or a decrease of 40.7% ($p < 0.001$). This suggests a significant reduction of pain after 6 months postoperatively. The 12-month postoperative NRS was significantly lower than the pre-operative NRS score of 6.00 down to 0.81, or a decrease of 86.5% ($p < 0.001$). This suggests a significant reduction of pain after 12 months postoperatively. The 12-month postoperative NRS was significantly lower than the 6-month postoperative NRS score of 3.56 down to 0.81, or a decrease of 77.2% ($p < 0.001$). This suggests a significant reduction of pain after 12 months postoperatively compared to 6 months postoperatively.

The 6-month postoperative ODI was significantly lower than the pre-operative ODI value of 58.38, down to 32.87, or a decrease of 43.7% ($p < 0.001$). This indicates a significant functional improvement after 6 months postoperatively. The 12-month postoperative ODI rate was significantly lower than the pre-operative ODI value of 58.38 dropping to 8.38 or a decrease of 85.6% ($p < 0.001$). This indicates a significant functional improvement after 12 months postoperatively. The 12-month postoperative ODI was significantly lower than the 6-month postoperative ODI rate from 32.87 to 8.38 or a decrease of 74.5% ($p < 0.001$). This indicates a significant functional improvement after 12 months postoperatively compared to 6 months postoperatively.

There were significant functional improvements after 6 months and 12 months postoperative than before surgery ($p < 0.001$). Table above shows before the operation there were 7 subjects (43.8%) who were paralyzed and 9 subjects (56.3%) who severe disability, whereas in 6 months postoperatively no more paralyzed subjects and the remaining 2 subjects with severe disability. At 12 months postoperative follow-up, all subjects (100%) had minimal disability. (Tab 2)

Table 1. Distribution characteristics of study subjects.

Variable	N (%)	Range	Mean ± SD
Male	10 (62,5%)	-	-
Female	37 (37,5%)	-	-
L3 - L4 location	5 (31,3%)	-	-
L4 - L5 location	11 (68,8%)	-	-
Age (year)	-	44 - 78	57 ± 8,0
BMI (kg/m ²)	-	20,3 - 28,3	24,5 ± 2,2

Discussion

Studies of these 16 patients showed significant pain reduction in patients with a period of 12 months postoperatively compared with 6 months postoperatively performed by the same surgeon. And in addition to the disability measurements with the Oswestry Disability Index also showed significant changes with the initial disability of 58.38% (severe disability) to 32.87% (moderate disability) after 6 months and 8.38% (minimal disability) after 12 months post operation.

Previous study by Trouillier et al., reported that the average ODI rate for the entire group was 58% before surgery, 26% after 12 months, and 30% after 42 months. Pain scores also decreased from pre-operative values of 80%, to 30% after one year, and 45% after 3.5 years. [4]

Lin, et al., reported a satisfactory clinical outcome of 74% and a 93% fusion rate in 71 patients with spinal stenosis undergoing PLIF procedures. Hutter studied 142 patients with spinal stenosis treated with PLIF and obtained good results at 78% as well as 91% fusion. [6]

Based on the results of the Ramani study, elderly patients with Lumbar spinal stenosis with instability were suitable patients for the PLIF procedure. The patients would have improved clinical symptoms, function, and actual patient satisfaction (91%), at least at short time follow-up (1 year). [7]

Atlas S.J., et al, reported that among patients with lumbar spinal stenosis completing 8- to 10-year follow-up, low back pain relief, predominant symptom improvement, and satisfaction with the current state were similar in patients initially treated surgically or nonsurgically. However, leg pain relief and greater back-related functional status continued to favor those initially receiving surgical treatment. [8]

In the patients who primarily complain of radiculopathy with an underlying biomechanically stable spine, a decompression surgery alone using a less invasive technique may be sufficient. Preoperatively, with the presence of indicators such as failed back surgery syndrome (revision surgery), degenerative instability,

Table 2. Comparison of disabilities before surgery, 6 months and 12 months postoperatively.

Disability		Time		
		Before surgery	6 months post operatively	12 months post operatively
Minimal	N	0	0	16
	%	0,0%	0,0%	100,0%
Moderate	N	0	14	0
	%	0,0%	87,5%	0,0%
Severe	N	9	2	0
	%	56,3%	12,5%	0,0%
Crippled	N	7	0	0
	%	43,8%	0,0%	0,0%

considerable essential deformity, symptomatic spondylolysis, refractory degenerative disc disease, and adjacent segment disease, lumbar fusion is probably recommended. Intraoperatively, in cases with extensive decompression associated with a wide disc space or insufficient bone stock, fusion is preferred. [9]

Okuda S., et al, reported high satisfaction rate to PLIF and significant correlation between patient and surgeon-based surgical outcomes were detected. Postoperative permanent motor loss and multiple revision surgery were the major factors related to a negative response. [10]

This is in line with the aim of this study that PLIF procedures with cage can improve the functional outcome of patients with lumbar spinal stenosis, characterized by reduced pain and reduced functional disability daily. The PLIF procedure with cage allows restoration of altitudes between the vertebral bodies is sufficient, allowing for nerve decompression while maintaining the posterior structure, and also allowing 360 degree fusion through a single incision. [4, 11].

Conclusion

There is improvement of functional outcome after the posterior Lumbar Interbody Fusion procedure with cage in patients with lumbar spinal stenosis. PLIF with cage can be used as one of the treatment options for treating patients with lumbar spinal stenosis, but advanced research is needed to assess radiological fusion and to compare PLIF procedures with cage with other surgical procedures.

References

1. Zingg P.O., Boos N. 2008. Lumbar Spinal Stenosis In: Boos N., Aebi M., editors: Spinal Disorders Fundamentals of Diagnosis and Treatment. Berlin: Springer. p. 513-33.
2. Tomita K. 2002. Diagnosis and Treatment of Lumbar Spinal Canal Stenosis. Japan Medical Association Journal, 128 (12): 1790-1794.
3. Rajagopal T.S., Marshall R.W. 2010. Focus On Understanding and Treating Spinal Stenosis. The Journal of Bone and Joint Surgery.
4. Trouillier. H., Birkenmaier C. Rauch A. Weiler C., Kauschke T. Reffior H.J. 2006. Posterior lumbar interbody fusion (PLIF) with cages and local bone graft in the treatment of spinal stenosis. Acta Orthopaedica Belgica, 72, 460-466.
5. Mobbs R.J., Phan K., Malham G., Seex K., Rao P.J. 2015. Lumbar Interbody Fusion: Techniques, Indications and Comparison of Interbody Fusion Options including PLIF, TLIF, MI-TLIF, OLIF/AT-P,LLIF and ALIF. Journal of Spine Surgery, 1 (1): 2-18.
6. Coric D., Branch C.L. 1997. Posterior lumbar interbody fusion in the treatment of symptomatic spinal stenosis. Neurosurgical Focus, 3(2).
7. Ramani, P.S., Pawar S., Babhulkar S. 2014. Dilemma in the Surgical Management of Lumbar Canal Stenosis. The Journal of Spine Surgery, 1(1): 1-11.
8. Atlas S.J., Keller R.B., Wu Y.A., Deyo R.A., Singer D.E. 2005. Long-Term Outcomes of Surgical and Nonsurgical Management of Lumbar Spinal Stenosis: 8 to 10 Year Results from the Maine Lumbar Spine Study. Spine, 30 (8): 8936-943.
9. Kashani F.O., Ebrahim Ghayem Hasankhan E.G., Ashjazadeh A. 2014. Lumbar Spinal Stenosis: Who Should Be Fused? An Updated Review. Asian Spine Journal, 8 (4): 521-20.
10. Okuda S., Fujimori T., Oda T., Maeno T., Yamashita M., Matsumoto T., et al. 2017. Factors Associated with Patient Satisfaction for PLIF: Patient Satisfaction analysis. Spine Surgery and Related Research, 1(1): 20-26.
11. Satyanarayana J., Reddy G., Kund A.S. 2015. Outcome of Single Level Instrumented Posterior Lumbar Interbody Fusion. IOSR Journal of Dental and Medical Sciences, 14(9): 79-81.



Spontaneous intramural esophageal hematoma: Complete healing without surgical intervention

Novruzov Namig, MD, PhD¹
Aynur Safiyeva, MD, PhD¹
Emin Mammadov, MD¹

¹ Central Customs Hospital, General Surgery Department, Azerbaijan.

² Central Customs Hospital, Gastroenterology Department, Azerbaijan.

³ Central Customs Hospital, Radiology Department, Azerbaijan.

We report 6 rare case of spontaneous intramural esophageal hematoma (SIEH) that presented with chest pain which was initially clinically suspected to be due to aortic dissection. The case was diagnosed by endoscopy and multidetector computed tomography. SIEH may represent an intermediate stage between Mallory-Weiss tear and Boerhaave's syndrome. In our experience, computed tomography is very informative as noninvasive examination for an early diagnosis of SIEH and for differentiation of aortic and other mediastinal diseases with acute chest pain. Conservative treatment with proton pump inhibitors and observation resulted in complete healing of patients without surgical intervention.

Keywords: Boerhaave's syndrome, spontaneous esophageal intramural hematoma, Mallory-Weiss tear

Correspondence:

Novruzov Namig, MD, PhD
Central Customs Hospital,
General Surgery Department
118, K.Kazimzadeh str. AZ1065,
Baku, Azerbaijan.
Phone: +99450 374 81 22
Email: surgeon.06@mail.ru

Introduction

Spontaneous intramural esophageal hematoma (SIEH) is a rare complication that is known as esophageal apoplexy, intramural hemorrhage or intramural dissection in literature. Intramural hematomas can develop in six possible pathogenic causes: hemostasis, emetogenic origin, spontaneous, barotrauma or food trauma, iatrogenic - intravenous catheterization or endoscopic examination, associated with aortic diseases [1, 2, 3].

Material and Methods

In this study, the results of 6 patients with spontaneous intramural esophagus hematoma were evaluated retrospectively.

Patients had complaints of retrosternal pain, dysphagia and hematemesis, depending on esophageal hematoma. 4 of the patients were women and 2 were men. One of the patients after coronary artery bypass surgery and the other patient on cardio-

logical condition after coronal angiography was admitted persistent warfarin. Other patients did not have anamnesis of trauma or anticoagulant use. In one of the women's, a distal esophageal stricture due to achalasia and persistent disturbance resulted hematoma (change the sentence). Three of the patients were transferred to our clinic with Mallory-Weiss's syndrome and others with Esophageal varices bleeding suspicions. Patients were stable in physical, abdominal, hemodynamic, cardiac, and respiratory examinations.

Results

Although initial examination may have doubts about aortic dissection, in radiographically thoracic computed tomography (CT) scan visualized the large intramural hematoma, which formed stenosis by compressing to the lumen of the esophagus. There was no perforation or intramural proliferation in oral contrast tomography (Fig. 1).

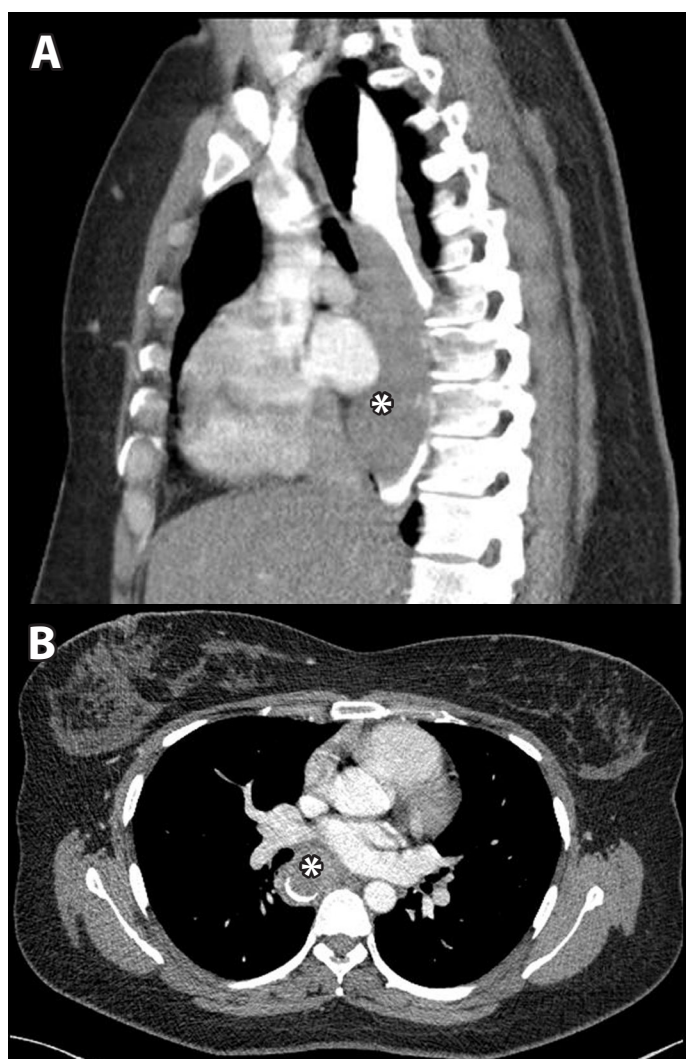


Figure 1. Sagittal (A) and axial (B) computed tomography (CT) images of the thorax oral administration of contrast medium: large elongated intramural hematoma (star) narrowing esophageal lumen.

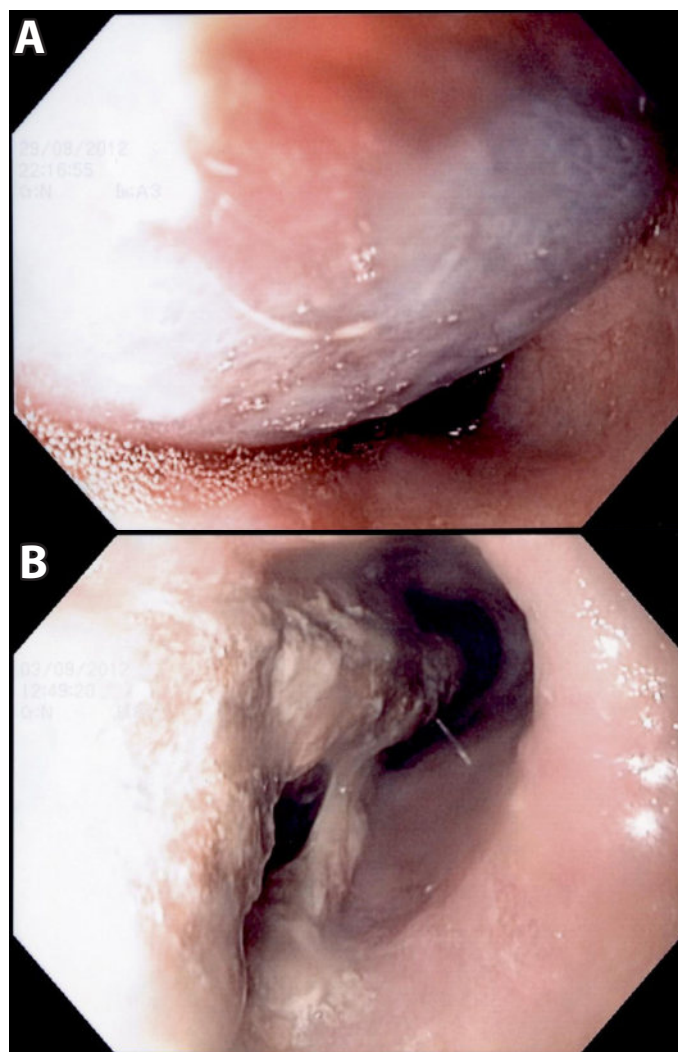

Figure 2. Endoscopic examination: the obstructing mass of esophagus at initial (A) and 5 days later (B) showed complete resolution of the hematoma.

In an emergency endoscopic examination, the columnar submucosal hematoma was found in two cases at a distance from the cervical esophagus and in four patients from the level of the carina to the lower esophageal sphincter level. All patients were prescribed medical treatment of proton pump inhibitors. The control endoscopic examination was performed 5 or 7 days later, showed the decrease size of hematoma (Fig. 2). Patients were asymptomatic and able to tolerate a complete diet. Resolution of the esophageal hematoma was observed radiologically two weeks later.

Discussion

Esophageal damage clinically is being observed as laceration of the mucosa of gastroesophageal junction or cardial part of the stomach - Mallory-Weiss tipping, transmural laceration of all the esophageal walls - Boerhaave syndrome and as sponta-

neous intramural esophageal hematoma (SIEH). Some authors regard intramural hematoma as moderate congestion between mentioned mucosal and transmural injuries.

Mallory-Weiss syndrome is clinically observed with hematemesis in 30-80% of cases after coughing or large vomiting and endoscopic examination is the first choice for diagnosis [1, 4].

Boerhaave syndrome is classically presented with the Mackler triad; vomiting, pain in the chest and subcutaneous emphysema [5-7]. Pathologic radiological signs for esophagus perforation are extravasation of the oral contrast and detection of the free air in the mediastinum or in peritoneal cavity [8, 9].

Intramural esophagus hematoma clinically manifests with retrosternal pain, dysphasia, and hematemesis. Because retrosternal pain is not a specific symptom for SIEH, it should be differentiated with acute aortic dissection, aortic aneurysm laceration, acute myocardial infarction, peptic ulcer perforation and acute pancreatitis.

Mallory-Weiss syndrome is mainly treated with parenteral nutrition and intravenous analgesics. Boerhaave syndrome require aggressive surgical treatment in the early period as it causes fatal mediastinitis with 10-50% mortality [1, 10, 11].

Conclusion

Computer tomography is very informative as noninvasive examination for an early diagnosis of IEHS and for differensation of dissection of aortic aneurysm and other acute mediastinal pathology. In our experience, early diagnostics with endoscopic and radiological examination, conservative treatment with proton pump inhibitors and observation resulted in complete healing of patients without surgical intervention.

References

1. Restrepo CS, Lemos DF, Ocazonez D, Moncada R, Gimenez CR. Intramural hematoma of the esophagus: a pictorial essay. *Emerg Radiol* 2008;15:13–22.
2. Borrie J, Sheat J. Spontaneous intramural oesophageal perforation. *Thorax* 1970;25:294–300.
3. Jalihal A, Jamaludin AZ, Sankarakumar S, Chong VH. Intramural hematoma of the esophagus: a rare cause of chest pain. *Am J Emerg Med* 2008;26:843.
4. Younes Z, Johnson DA. The spectrum of spontaneous and iatrogenic esophageal injury: perforations, Mallory-Weiss tears, and hematomas. *J Clin Gastroenterol* 1999;29:306–17.
5. Cullen SN, McIntyre AS. Dissecting intramural haematoma of the oesophagus. *Eur J Gastroenterol Hepatol* 2000;12:1151–62.
6. Enns R, Brown JA, Halparin L. Intramural esophageal hematoma: a diagnostic dilemma. *Gastrointest Endosc* 2000;51:757–9.
7. Maher MM, Murphy J, Dervan P, O'Connell D. Aortooesophageal fistula presenting as a submucosal oesophageal haematoma. *Br J Radiol* 1998;71:972–4.
8. Di Maggio EM, Preda L, La Fianza A, Dore R, Pallavicini D, Di Maggio G, Campani R. Spontaneous rupture of the esophagus (Boerhaave syndrome): computerized tomography diagnosis in atypical clinical presentation. *Radiol Med (Torino)* 1997;94:52–7.
9. Ghanem N, Althoefer C, Springer O, Furtwängler A, Kotter E, Schäfer O, Langer M. Radiological findings in Boerhaave's syndrome. *Emerg Radiol* 2003;10:8–13.
10. Barone JE, Robilotti JG, Comer JV. Conservative treatment of spontaneous intramural perforation (or intramural hematoma) of the esophagus. *Am J Gastroenterol* 1980;74:165–7.
11. Lewis AM, Dharmarajah R. Walked in with Boerhaave's. *Emerg Med J* 2007;24:e24.



Successful decision-making for therapy of the patient with a floating thrombus attached to ruptured atherosclerotic plaque in the ascending aorta

Tomasz Stankowski, MD¹
Dr. med. Vusal Hajiyev, MD¹
Dr. med. Alexander Bauer, MD¹
Dr. med. Oliver Grimmig, MD¹
Prof. Dr. med. Dirk Fritzsche, MD¹

¹ Sana Heart Center Cottbus, Cottbus, Germany

Correspondence:

Dr. med. Vusal Hajiyev, MD
Sana Heart Center Cottbus
Cottbus, Germany.
Phone: +49 355 4800
Email: vusal.hajiyev@sana.de

Peripheral artery thromboembolism caused by free-floating thrombus attached to ruptured atherosclerotic plaque in the ascending aorta occurs extremely rare and can lead to serious complications. There are different therapeutic strategies but still no consensus. We present a 59-year-old patient where we decided for emergent operation.

Keywords: thromboembolism, floating thrombus, ascending aorta, atherosclerotic plaque.

Introduction

Intracardiac thrombus formation caused by cardiac arrhythmia or prosthetic valve endocarditis are a common reasons of peripheral arterial thromboembolism. A thrombosed rupture of the ascending aorta with peripheral thromboembolic complications is a very rare case in cardiac surgery.

Case Report

A 59-year-old male was admitted to the emergency department due to a stabbing epigastric pain and vomiting. Computed tomography (CT) of the chest showed unidentified mass attached to the aortic plaque in ascending aorta, embolic infarctions of caudal left renal and two peripheral splenic segments. Transesophageal echocardiography (TEE) revealed proper morphology and function of the valves with normal left and right ventricular functions, excluded any intracardiac thrombi and confirmed the presence of a floating mass attached to the plaque in the ascending aorta, above the aortic valve (Fig. 1, 2). The patient underwent an emergency cardiac surgery. The operation was done through median sternotomy using cardiopulmonary bypass and blood cardioplegia for induction of

cardiac arrest. After transverse aortotomy, 3.0 × 3.0 cm solitary, ruptured to the tunica adventitia arteriosclerotic plaque located on the greater curvature of the ascending aorta, above the sinotubular junction was found. On the plaque was found 3.0 × 4.0 cm floating thrombus (Fig. 3). Subtotal resection of the plaque with an attached thrombus was performed and the aortotomy was closed using 4/0 polypropylene. Intraoperative TEE revealed good cardiac function, no evidence of aortic thrombus or dissection. Histopathological examination of the resected mass confirmed the above mentioned diagnosis of a thrombus. The postoperative recovery was uneventful and the patient was discharged after 8 days. Oral anticoagulation by means of vitamin K antagonists was given on second post-op day and the anticoagulation treatment was continued until the third postoperative month.

Discussion

Due to the relative rarity of this disease, we did not find the clear recommendations for this kind of unusual case. Conservative treatment could be associated with embolization, aortic rupture of the ulcerated atherosclerotic plaque, intramural hematoma

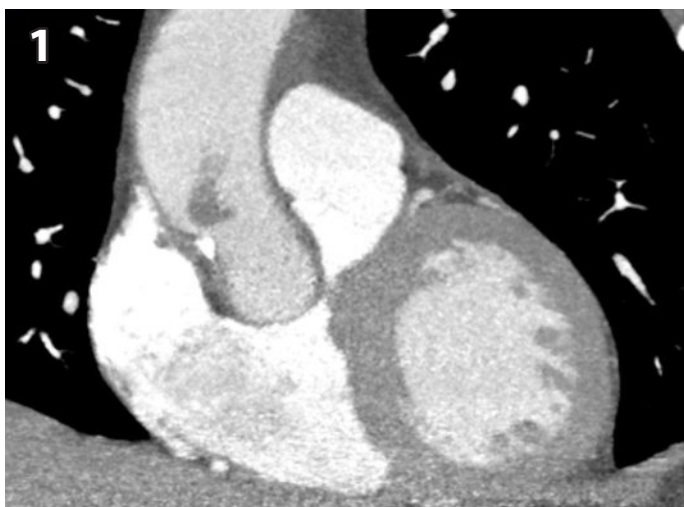


Figure 1.
Unidentified mass in the ascending aorta above the right sinus of Valsalva. Preoperative CT of the chest.

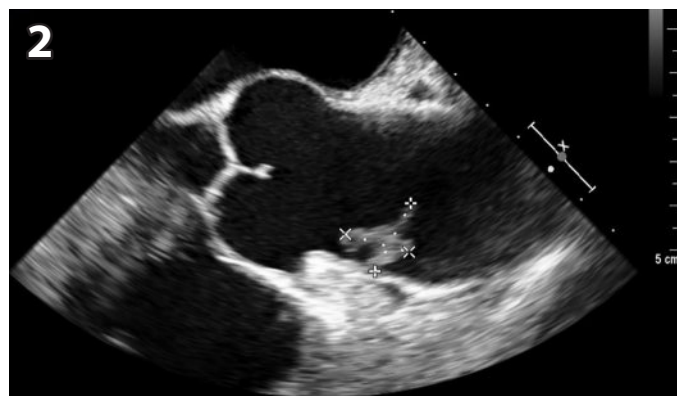


Figure 2.
Unidentified mass in the ascending aorta above the right sinus of Valsalva. Preoperative transesophageal echocardiography.

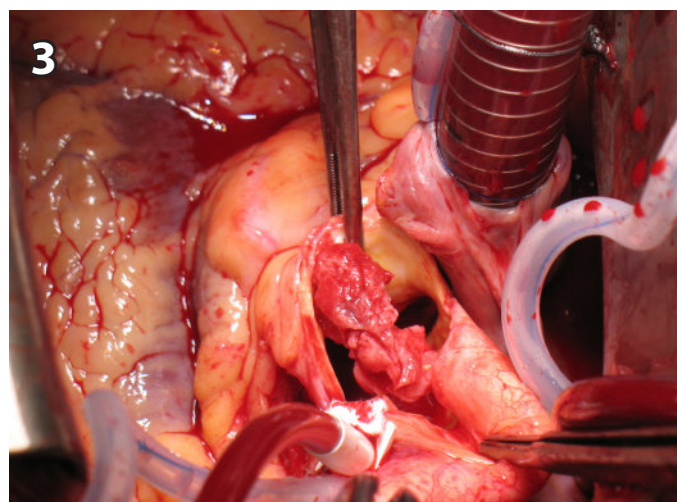


Figure 3.
Intraoperative photograph. Thrombus attached to the atherosclerotic plaque, 2 cm above the right coronary ostium.

or even aortic dissection [1], therefore we recommend an immediately thrombectomy. The majority of fund studies described the urgent thrombectomy as the only sensible solution in these group of patients [1,2,3]. On the other hand, some authors performed the surgical intervention after primarily heparin treatment with satisfactory results, however it was also signaled, that the delay of the surgery might cause fragmentation of the thrombus [3]. There is little evidence to suggest complete dissolution of the mobile thrombus after intravenous heparin, however more than half of patients required still thrombectomy [4]. Successful thrombolysis of structure in the aortic-arch was observed in one paper [5], the author suggested that this kind of treatment might be a promising therapy in selected patients, however further studies are needed, therefore the effectiveness should be evaluated with caution.

Conclusion

In our opinion, thrombus in the ascending aorta attached to the atherosclerotic plaque should be operated as emergency to avoid further fragmentation of the structure and consequences such as thromboembolization, plaque rupture or aorta dissection.

References

1. Sabetai MM, Conway AM, Hallward G, Bapat V. Ascending aorta thrombus adjacent to a cholesterol-rich plaque as the source of multiple emboli. *Interactive Cardiovascular and Thoracic Surgery*. 2013;16(3):389-390. doi:10.1093/icvts/ivs490.
2. Sodian R, Bauer M, Weng YG, Siniawski H, Koster A, Hetzer R. Floating nonocclusive thrombus in the ascending aorta. *Ann Thorac Surg*. 2002 Aug;74(2):588-90.
3. Sawada T, Shimokawa T. Giant thrombus in the ascending aorta that caused systemic embolism. *Interact Cardiovasc Thorac Surg*. 2011 Jun;12(6):1048-50. doi: 10.1510/icvts.2011.266445. Epub 2011 Mar 21.
4. Choukroun EM, Labrousse LM, Madonna FP, Deville C. Mobile thrombus of the thoracic aorta: diagnosis and treatment in 9 cases. *Ann Vasc Surg*. 2002 Nov;16(6):714-22. Epub 2002 Nov 7.
5. Hausmann D, Gulba D, Bargheer K, Niedermeyer J, Comess KA, Daniel WG. Successful thrombolysis of an aortic-arch thrombus in a patient after mesenteric embolism. *N Engl J Med*. 1992 Aug 13;327(7):500-1.



Early IVC thrombosis after central shunt surgery in young adult with uncorrected tetralogy of Fallot

Samira A. Valiyeva, MD¹
Madina H. Yuzbashova, MD²
Prof. Ermanno Mazza¹
Rashad M. Mahmudov, MD, PhD, DSc³

¹ Department of Intensive Care Unit, Baku Heart Center of the Republican Diagnostics and Treatment Center

² Department of Pediatric Cardiology, Baku Heart Center of the Republican Diagnostics and Treatment Center

³ Department of Cardiovascular Surgery, Baku Heart Center of the Republican Diagnostics and Treatment Center

Correspondence:

Samira Valiyeva, MD

Department of Intensive Care Unit, Baku Heart Center of the Republican Diagnostics and Treatment Center

147 Tbilisi avenue,
Baku, Azerbaijan.

Phone: +99450 4942762

Email: samira_valiyeva@yahoo.com

As there is paucity of data about thrombosis of inferior vena cava (IVC) in adult patients with uncorrected cyanotic heart defects, including those with tetralogy of Fallot, revealing and reporting of such cases is necessary for development of their proper clinical management.

Because cardiac surgery is relatively new in Azerbaijan late uncorrected cyanotic cases with subsequent complications are still an issue in our country.

Here we describe a case of IVC thrombosis after placement of systemic-pulmonary bypass (Davidson's shunt) in a 26-year-old patient diagnosed with Fallot's tetralogy. As there were signs of pulmonary embolism in early postoperative period, the patient has undergone vena cava filter placement.

Keywords: IVC thrombosis, congenital heart disease in young adult, systemic to pulmonary shunts, tetralogy of Fallot.

Introduction

Venous thromboembolism can be described as a state of deep venous thrombosis (DVT) with possibility of migration of thrombi through veins toward pulmonary artery.

Usually, in cyanotic congenital heart defects there is a connection between atria or ventricles that in case of regurgitation from right to left causes embolism of brain vessels with subsequent stroke [1, 2].

Inferior vena cava (IVC) thrombosis is quite alike DVT concerning etiology. The hypercoagulation state associated with hematological problems, neoplasm, venous stasis, surgery or a trauma is a main causative factor [3, 4].

Also patients with cyanotic heart defects have compensatory increased hematocrit that in turn increases blood viscosity, which contributes to easy formation of thrombi. There are also anomalies of coagulation and haemostatic, including those of fibrinolysis, in patients with congenital heart defects. The rate of mentioned anomalies is between

20 to 60%. Children with congenital heart defects that have hematocrit more than 60% often prone to develop thrombosis. [5]

Case Presentation

A 26-year-old male patient applied to our clinic complaining of breathlessness, cyanosis aggravated by motion, loose cough and stiffness in right extremities. His medical history revealed left-sided ischemic brain stroke 3 months before admission. Also, 2 months before admission he had an episode of massive haemoptysis. Physical examination revealed lean body constitution with weak development of subcutaneous fat and muscles. There were deformations of rib cage, acrocyanosis and nail clubbing. Oxygen saturation was 60-67% during the rest and inhalation of 2 l/min oxygen. Echocardiography confirmed diagnosis of Fallot's tetralogy with double vessels emerging from right ventricle (DORV Fallot type), and with hypoplastic pulmonary arteries. Right

(RPA), left (LPA) and main (MPA) pulmonary arteries measured 7, 4 and 16 mm, respectively. Contrast enhanced computer tomography (CT) revealed multiple aorta-pulmonary collaterals, thus further confirming the diagnosis. According to CT scans, the dimensions of pulmonary artery were determined as following: RPA – 9 mm, LPA – 4.5 mm, MPA – 18 mm. His blood and biochemistry tests were as following: haematocrit – 44.7%, haemoglobin – 14g/dl, platelets- $269 \times 10^9/l$, international normalized ratio – 1.18, prothrombin index – 78%, creatinine – 73 $\mu\text{mol/l}$, total bilirubin – 16.2 $\mu\text{mol/l}$, alanine transferase (ALT) – 9.3 IU/ml, aspartate transaminase (AST) – 38.8 IU/ml.

Weighing up all pros and cons the patient was recommended to undergo central aortopulmonary shunt (Davidson) procedure.

On 06.09.2017 patient had been placed the Davidson's shunt number 10. During postoperative period, he received heparin infusion at 15 U/kg/h rate [6]. Despite of recommended dose we couldn't get appropriate control of coagulation. His saturation during the rest and inhalation of 2 l/min oxygen increased up to 80%. The patient was mobilized and postural drainage was performed on 2nd postoperative day. Beginning from the 2nd postoperative day heparin infusion was stopped and the patient was administered Aspirin at 100 mg/day. On the 3rd postoperative day, the patient was transferred to in-patient treatment unit. On the 4th postoperative day, the scleral icterus, oliguria, hepatomegaly, apathy, breathlessness and decrease in saturation (despite of increase of delivery of oxygen up to 60%) were revealed. Blood tests were as following: total bilirubin – 60.4 $\mu\text{mol/l}$, unconjugated bilirubin – 36.4 $\mu\text{mol/l}$, conjugated bilirubin – 24 $\mu\text{mol/l}$, ALT – 87.5 IU/ml, D-dimer – 3500ng/ml). Echocardiography revealed big and mobile thrombus in IVC. Taking in account clinical signs and all possible risks, we decided on urgent placement of cava filter. The procedure was followed by transfusion of heparin with subsequent administration of Warfarine, Clexane and Aspirin. On the 9th day, the patient's blood tests were as following: total bilirubin – 29 $\mu\text{mol/l}$, ALT – 35.2 IU/ml, AST – 20.7 IU/ml. The patient was discharged without any clinical signs (his saturation was 78-85% without additional delivery of oxygen).

Discussion

It can be speculated that thrombosis in our case was caused by high viscosity of the blood, as a consequence of the main disease. Also patient denied mobilization in early postoperative period. As it is noted in the guideline of 2014th year [8], patients with venous thromboembolism are at high risk for ischemic brain stroke. That is also true for our patient; as he had stroke in the past probably due to DVT. We took in account the risk of repeated venous thrombosis. However, according to literature, the risk of subsequent venous thrombosis in such patients is 2% during 2 weeks, 6.4% during three months and 8% during 6 months, despite of usage of anticoagulants. Many patients with clinically manifesting DVT experience a thrombosis of pulmonary artery in 40-50% of cases. [7-9].

Husler et al., described 40 cases of thrombosis of inferior vena cava, including 6 patients with cyanotic and 4 patients with non-cyanotic heart defects [8].

Our patient developed thrombi despite of constant 2 days-long infusion of anticoagulant in sufficient doses. As there was a history of ischemic brain stroke, most probably the patient already had the DVT before admission. Also patient might have resistance to heparin. The most common cause of resistance to heparin is deficiency of anti-thrombin, which is necessary for anticoagulant effect of heparin. The deficiency can be congenital due to low synthesis, or it can be acquired because of disseminated coagulation syndrome or, due to high doses of heparin used during operation for extracorporeal circulation [10].

As there were not external factors listed above, we consider that our patient had congenital deficiency of anti thrombin. However, we don't have appropriate facilities to confirm this.

After placement of filter in IVC and administration of warfarine the thrombus has decreased in dimension and no episodes of recurrent thrombosis were noted.

Conclusion

According to described experience, one can speculate about high risk of deep vein thrombosis and IVC thrombosis in patients with cyanotic heart defects, particularly in adult cases. Predisposing factors may include disturbances of coagulation and insufficiency of anti thrombin and, hypodynamia, which we consider as a key factor in our case.

References

1. Shuiab A. Cerebral infarction and ventricular septal defect. *Stroke*. 1989 Jul 1;20(7):957-8.
2. Ucar O, Golbasi Z, Gulel O, Yildirim N. Paradoxical and pulmonary embolism due to a thrombus entrapped in a patent foramen ovale. *Texas Heart Institute Journal*. 2006;33(1):78-80.
3. Anderson FA, Wheeler HB, Goldberg RJ, Hosmer DW, Patwardhan NA, Jovanovic B, Forcier A, Dalen JE. A population-based perspective of the hospital incidence and case-fatality rates of deep vein thrombosis and pulmonary embolism. *Arch intern med*. 1991 May;151(5):933-8.
4. McAree BJ, O'Donnell ME, Boyd C, Spence RA, Lee B, Soong CV. Inferior vena cava thrombosis in young adults—a review of two cases. *The Ulster medical journal*. 2009 May;78(2):129.
5. Nichols DG, Greeley WJ, Lappe DG, Ungerleider RM, Cameron DE, Spevak PJ, Wetzel RC. *Critical Heart Disease in Infants and Children E-Book*. Elsevier Health Sciences; 2006 Aug 29: 371
6. Depts.washington.edu. (2014). Heparin Infusion Guidelines | Anticoagulation Services. [online] Available at: <https://depts.washington.edu/anticoag/home/content/heparin-infusion-guidelines> [Accessed 27 May 2018].
7. Boris JR, Harris MA. The use of anticoagulation in pediatric cardiac disease. *Images in paediatric cardiology*. 2003 Jul;5(3):1.
8. Häusler M, Hübner D, Delhaas T, Mühler EG. Long term complications of inferior vena cava thrombosis. *Archives of disease in childhood*. 2001 Sep 1;85(3):228-33.
9. Büller HR, Agnelli G, Hull RD, Hyers TM, Prins MH, Raskob GE. Anti-thrombotic therapy for venous thromboembolic disease: the Seventh ACCP Conference on Antithrombotic and Thrombolytic Therapy. *Chest*. 2004 Sep 1;126(3):401S-28S.
10. Maurin N. [Heparin resistance and antithrombin deficiency]. *Med Klin (Munich)*. 2009 Jun 15;104(6):441-9. doi: 10.1007/s00063-009-1093-8. Epub 2009 Jun 16. Review. German.

WMA International Code of Medical Ethics

Adopted by the 3rd General Assembly of the World Medical Association, London, England, October 1949 and amended by the 22nd World Medical Assembly, Sydney, Australia, August 1968 and the 35th World Medical Assembly, Venice, Italy, October 1983 and the 57th WMA General Assembly, Pilanesberg, South Africa, October 2006.

DUTIES OF PHYSICIANS IN GENERAL

- A PHYSICIAN SHALL always exercise his/her independent professional judgment and maintain the highest standards of professional conduct.
- A PHYSICIAN SHALL respect a competent patient's right to accept or refuse treatment.
- A PHYSICIAN SHALL not allow his/her judgment to be influenced by personal profit or unfair discrimination.
- A PHYSICIAN SHALL be dedicated to providing competent medical service in full professional and moral independence, with compassion and respect for human dignity.
- A PHYSICIAN SHALL deal honestly with patients and colleagues, and report to the appropriate authorities those physicians who practice unethically or incompetently or who engage in fraud or deception.
- A PHYSICIAN SHALL not receive any financial benefits or other incentives solely for referring patients or prescribing specific products.
- A PHYSICIAN SHALL respect the rights and preferences of patients, colleagues, and other health professionals.
- A PHYSICIAN SHALL recognize his/her important role in educating the public but should use due caution in divulging discoveries or new techniques or treatment through non-professional channels.
- A PHYSICIAN SHALL certify only that which he/she has personally verified.
- A PHYSICIAN SHALL strive to use health care resources in the best way to benefit patients and their community.
- A PHYSICIAN SHALL seek appropriate care and attention if he/she suffers from mental or physical illness.
- A PHYSICIAN SHALL respect the local and national codes of ethics.

DUTIES OF PHYSICIANS TO PATIENTS

- A PHYSICIAN SHALL always bear in mind the obligation to respect human life.
- A PHYSICIAN SHALL act in the patient's best interest when providing medical care.
- A PHYSICIAN SHALL owe his/her patients complete loyalty and all the scientific resources available to him/her. Whenever an examination or treatment is beyond the physician's capacity, he/she should consult with or refer to another physician who has the necessary ability.
- A PHYSICIAN SHALL respect a patient's right to confidentiality. It is ethical to disclose confidential information when the patient consents to it or when there is a real and imminent threat of harm to the patient or to others and this threat can be only removed by a breach of confidentiality.
- A PHYSICIAN SHALL give emergency care as a humanitarian duty unless he/she is assured that others are willing and able to give such care.
- A PHYSICIAN SHALL in situations when he/she is acting for a third party, ensure that the patient has full knowledge of that situation.
- A PHYSICIAN SHALL not enter into a sexual relationship with his/her current patient or into any other abusive or exploitative relationship.

DUTIES OF PHYSICIANS TO COLLEAGUES

- A PHYSICIAN SHALL behave towards colleagues as he/she would have them behave towards him/her.
- A PHYSICIAN SHALL NOT undermine the patient-physician relationship of colleagues in order to attract patients.
- A PHYSICIAN SHALL when medically necessary, communicate with colleagues who are involved in the care of the same patient. This communication should respect patient confidentiality and be confined to necessary information.

Azerbaijan Medical Association

ABOUT

The Azerbaijan Medical Association (AzMA) is the country's leading voluntary, independent, non-governmental, professional membership medical organization for physicians, residents and medical students who represent all medical specialties in Azerbaijan.

Association was founded by Dr. Nariman Safarli and his colleagues in 1999. At the founding meeting, the physicians adopted the Statutes and Code of Ethics of the Association. The AzMA was officially registered by Ministry of Justice of Azerbaijan Republic in December 22, 1999.

Since its inception, the AzMA continues serving for a singular purpose: to advance healthcare in Azerbaijan.

- Founded in 1999, the AzMA provides a way for members of the medical profession to unite and act on matters affecting public health and the practice of medicine.
- We are the voice of physicians who support the need for organized medicine and want to be active within their profession.
- We are the representative for Azerbaijan doctors on the world-wide level and the voice of Azeri physicians throughout the world.

MISSION

The mission of the Azerbaijan Medical Association -is to unite all members of the medical profession, to serve as the premier advocate for its members and their patients, to promote the science of medicine and to advance healthcare in Azerbaijan.

GOALS

- Protect the integrity, independence, professional interests and rights of the members;
- Promote high standards in medical education and ethics;
- Promote laws and regulation that protect and enhance the physician-patient relationship;
- Improve access and delivery of quality medical care;
- Promote and advance ethical behavior by the medical profession;
- Support members in their scientific and public activities;
- Promote and coordinate the activity of member-specialty societies and sections;
- Represent members' professional interests at national and international level;
- Create relationship with other international medical associations;
- Increase health awareness of the population.

The association's vision for the future, and all its goals and objectives are intended to support the principles and ideals of the AzMA's mission.

INTERNATIONAL RELATIONSHIPS

Since its establishment, AzMA built close relationships with many international medical organizations and national medical associations of more than 80 countries. The following are the AzMA's international affiliations:

- Full membership in the World Medical Associations (WMA) (since 2002)
- Full membership in the European Forum of Medical Associations (EFMA) (since 2000)
- Full membership in the Federation of Islamic Medical Associations (FIMA) (since 2002)
- Associate membership in the European Union of Medical Specialists (UEMS) (since 2002)

Especially the year 2002 remained with memorable and historical events for AzMA such as membership to the World Medical Association (WMA). Today we are extremely pleased to represent our Association and to be a part of the WMA family.

MEMBERSHIP

A person with medical background, who accepts and follows the AzMA Statutes and AzMA Code of Ethics, may become a member of the Association. The Code of Ethics of the Association shall be the members' guide to professional conduct.

Membership in the AzMA is open to:

- Physicians residing and practicing in Azerbaijan and in abroad.
- Medical students enrolled at medical universities or schools
- Retired physicians

Members can access a special members only area of the AzMA website designed to provide the most up-to-date, and timely information about organized medicine in our country.

To the non-member, we hope you'll discover, through our website how valuable Azerbaijan Medical Association is to medicine in Azerbaijan and will join us.

MEDICINE'S VOICE IN AZERBAIJAN

As the largest physician membership organization in Azerbaijan the AzMA devotes itself to representing the interests of physicians, protecting the quality of patient care and as an indispensable association of busy professionals, speaks out with a clear and unified voice to inform the general public and be heard in the highest councils of government.

The AzMA strives to serve as the Medicine's Voice in Azerbaijan.

•••

For more information, please visit our website:
www.azmed.az

for notes

**We work together for the
sake of healthy future of
Azerbaijan!**



Azerbaijan Medical Association

P.O. Box - 16, AZ 1000, Baku, Azerbaijan




Tel: +99412 492 80 92, +99450 328 18 88

info@azmed.az, www.azmed.az

Reach your Global Audience



For more advertising opportunities:

 www.amaj.az,
 advertising@amaj.az
 +99412 492 8092,
+99470 328 1888